

Concomitant megaloblastic anemia and myelodysplastic syndrome

Amal Khan, Adel Bensaleh, Anurag Saxena

ABSTRACT

Introduction: Megaloblastic Anemia (MBA) and Myelodysplastic Syndrome (MDS) are broadly regarded as mutually exclusive entities in the diagnostic workup of macrocytic anemia. MBA is a reversible form of ineffective hematopoiesis and MDS is an irreversible disorder of ineffective hematopoiesis manifested in part by karyotype anomalies due to DNA damage characterized by stem cell dysfunction. However, there is significant overlap in their clinical presentation and in investigatory parameters. **Case Report:** A 67-year-old man initially presented with insidious onset fatigue and during diagnostic workup was found to have marked pancytopenia, macrocytic anemia, a megaloblastic peripheral blood picture and reduced serum Vitamin B12 establishing the diagnosis of MBA. Replacement therapy resulted in moderate improvement. Persistence of pancytopenia led to a bone marrow examination. The combination of a hypercellular marrow with significant erythroid dysplasia and a clonal abnormality-t (9;11)(p22;q23) led to a diagnosis of myelodysplastic syndrome–unclassified

(MDS-U). **Conclusion:** This case suggests that MBA & MDS can occur simultaneously and clinicians should take into account concomitant existence during the workup, when pancytopenia persists after treatment or there are other features suspicious for MDS.

Keywords: Megaloblastic Anemia, Myelodysplastic Syndrome, Pancytopenia

How to cite this article

Khan A, Bensaleh A, Saxena A. Concomitant megaloblastic anemia and myelodysplastic syndrome. J Case Rep Images Pathol 2018;4:100026Z11AK2018.

Article ID: 100026Z11AK2018

doi: 10.5348/100026Z11AK2018CR

Amal Khan¹, Adel Bensaleh², Anurag Saxena³

Affiliations: ¹Graduate Student, Department of Community Health And Epidemiology, University of Saskatchewan, Saskatoon, Saskatchewan, Canada; ²Physician, Clinical Associate Professor, Department of Internal Medicine, University of Saskatchewan/Saskatchewan Health Authority, Prince Albert, Saskatchewan, Canada; ³Professor, Department of Pathology, University of Saskatchewan/ Saskatchewan Health Authority, Saskatoon, Saskatchewan, Canada

Corresponding Author: Anurag Saxena, MBBS, MD, M.Ed., MBA, FRCPC, FCAP, CHE, CCPE, Associate Dean, Post-graduate Medical Education, Room 402, St. Andrew's College, 1121 College Drive, Saskatoon, SK, S7N 0W3, Canada; Email: anurag.saxena@usask.ca

Received: 11 October 2018

Accepted: 11 December 2018

Published: 30 December 2018

INTRODUCTION

Megaloblastic anemias (MBA) are a group of disorders characterized by peculiar morphological appearance due to dysfunctional maturation of hematopoietic precursors in the bone marrow. The cause is usually deficiency of either cobalamine (Vit B12) or folate that leads to defects in the synthesis and repair of DNA. MBA may also arise because of inherited or acquired abnormalities affecting the metabolism of these vitamins or because of defects in DNA synthesis not related to cobalamine or folate [1]. Myelodysplastic syndromes (MDS) are characterized by ineffective hematopoiesis due to an acquired and persistent clonal abnormality, often associated with karyotype anomalies resulting in cytopenia(s), dysplasia in one or more of the major hemopoietic cell lines and a propensity to progress into acute myeloid leukemia [2].

In the evaluation of patients with macrocytic anemia, although MBA and MDS are distinctly exclusive entities,

there is, however, a significant overlap in clinical presentation, laboratory findings, pathological and cytogenetic features [3]. Often these two conditions are seen in the same age group i.e. elderly, median age MDS=70 Years [2], average age MBA \geq 70 Years [4] with vague symptoms of insidious onset fatigue and dyspnea. The diagnosis of MBA and MDS is relatively straight forward in most cases. However, morphological dysplasia as seen with MDS may be seen in Vit B12 deficiency or folate deficiency, alcohol excess, after cytotoxic chemotherapy, HIV infection and even in a minority of cells in the normal bone marrow [5]. For definitive diagnosis, assessment of disease severity and estimating prognosis, peripheral blood and bone marrow examination are most often performed [6]. The early morphological changes in MDS may be subtle - especially when only erythroid lineage is involved and many patients with normo- or macrocytic anemia in the elderly may be examples of MDS [7], as identified in one study where 15% of inpatients with unexplained cytopenias, macrocytosis or monocytosis ultimately proved to have MDS [8].

Pancytopenia encompasses a broad spectrum of differential diagnosis due to complex and multifactorial etiologies. The underlying diagnosis may be difficult, especially if there is no evidence of a neoplasm and often extensive studies are required to arrive at the precise diagnosis [9]. New onset pancytopenia can sometimes result from nutritional deficiencies of cobalamin or folate [10]. Hence, in all patients with pancytopenia and peripheral blood film showing megaloblastic processes, serum cobalamin and folate measurements are suggested [11]. Thus, in a patient with pancytopenia with no clinical or pathological features of multilineage dysplasia Vit B12 deficiency alone may be sufficient to explain pancytopenia reaching a definitive diagnosis of MBA. Our case report suggests otherwise, leaning more towards being wary of a seemingly innocent superficial clinicopathological picture.

CASE REPORT

A 67-year-old man who was found to have both Vit B12 deficiency and MDS. His initial presentation in the Emergency Room included features of general weakness, fatigue, malaise, a pre-syncope episode and weight loss. He had no regular medical follow up prior to this presentation and denied occupational exposure to radiation, industrial chemicals, chemotherapy (alkylating agents) or radiotherapy. The vital signs at this presentation were: blood pressure 89/31 mmHg, a heart rate of 99/min, respiratory rate 24/min and a temperature 37.4 °C and oxygen saturation of 99% at room air. Physical examination identified a pale, well appearing elderly man without clinically appreciable lymphadenopathy or hepato-splenomegaly. There was no evidence of autoimmune diseases i.e. rash or areas of vitiligo, swollen or inflamed joints. There was atrial

fibrillation identified by electrocardiography. Chest radiograph was unremarkable. The CT scan detected mild splenomegaly.

There was pancytopenia at presentation. Relevant parameters are shown in (Table 1) prior to definitive diagnosis. At admission the reticulocyte count was $72 \times 10^6/L$. In the peripheral blood film blasts, significant dysplastic changes, leukoerythroblastic reaction or abnormal lymphoid cells were not seen.

The levels of analytes were as follows: Vit B12-52 pmol/L (reference range: >200 pmol/L), Methyl Malonic Acid - 2.9 $\mu\text{mol/L}$ (reference range: less than 0.4 $\mu\text{mol/L}$), Carcinoembryonic antigen - 3.7 ng/ml (reference range: less than 5 ng /ml), PSA - 2.8 ng (reference range: less than 4 ng/ml), total Serum Protein - 60 g/L (reference range 64-82 g/L) and Serum Albumin - 37 g/L (reference range 35-50 g/L). Iron studies were within reference range. Antibodies to intrinsic factor were absent and the Coombs test was negative. Investigations for other concurrent autoimmune endocrinopathies were negative. Serology for Hepatitis B and Hepatitis C was negative. There was no monoclonal band on serum protein electrophoresis (SPEP).

Blood cultures taken earlier showed no growth.

In view of vitamin B12 deficiency, the patient was treated with oral Vit B12 and parenteral replacement therapy along with oral iron and folic acid on the 6th day of the admission. After one week of replacement therapy, there was moderate improvement in the hemoglobin level reaching 127 g/L and 147 g/L on the 20th and 30th day of the commencement of Vit B12 therapy. The WBC, platelets and MCV recovered to within reference range.

The presence of pancytopenia, had prompted for a bone marrow examination. The marrow was hypercellular (approximately 98%). Focally aggregates of erythroid precursors (positive for glycophorin A and E-cadherin) were present and there was maturation arrest. Dyserythropoiesis was identified by defective hemoglobinization of cytoplasm, nuclear budding, and binucleate erythroid precursors. Blasts were not increased (2.4%). Mild dysplastic changes were observed in less than 10% of megakaryocytes (Figures 1-2).

Cytogenetic analysis of the cultured bone marrow cells identified a clone with an abnormal male karyotype characterized by a translocation between the short arm of chromosome 9 and the long arm of chromosome 11 with breakpoints estimated to be with bands 9p22 and 11q23 in 2 out of 20 metaphase cells examined. Fluorescence in-situ hybridization performed on the interphase nuclei with the KMT2A (MLL) dual color, break apart probe (Abbott Molecular, Des Plaines, IL) revealed that this translocation - t(9;11) (p22;q23) - did not involve the MLL gene. In the latter case, a very small insertion of chromosomal material that includes a MLL translocation partner gene into the MLL gene could result in increased spacing between the 5' Spectrum Green and the 3' Spectrum Red signals compared to the other locus by FISH and easily go undetected. This would appear as

Table 1: Relevant complete blood count values, in the first column the text with in brackets in reference range and units

	At Admission	During diagnostic workup (Day 3)	During diagnostic workup (Day 7) Bone marrow exam	During diagnostic workup (Day 12)	Treatment with B12/ folate/iron commenced Day 18)	At 20 days post completion of treatment with B12	At 30 days post completion of treatment with B12	At 6 months after admission	At 1-5 years after admission	At 2.5 years after admission
WBC (4.8-10.8 x 10 ⁹ /L)	1.0	1.2	1.2	1.4	2.6	5.0	6.7	9.3	7.4	6.6
Hemoglobin (g/L) (126-180 x g/L)	50	77	76	97	70	127	147	181	175	169
MCV(fL) (76-96 fL)	112	95	96	95.1	98	99.1	100	89.6	96.2	90.5
Platelets (140-440 x 10 ⁹ /L)	47	47	48	48	140	394	223	209	193	159

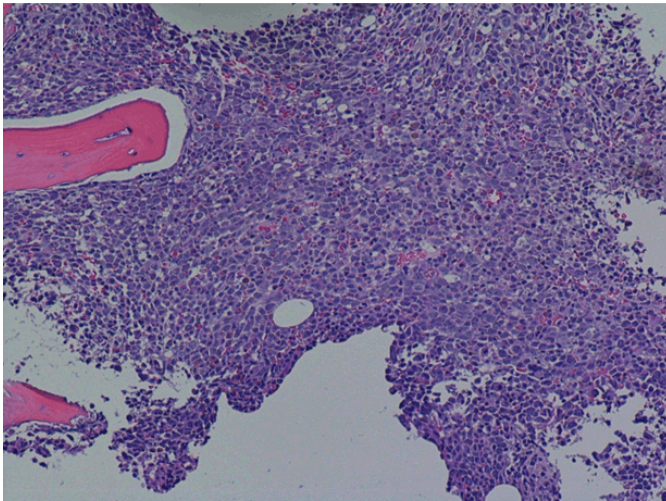


Figure 1: Trephine biopsy, H & E staining, 20x, hypercellular marrow with trilineage hematopoiesis.

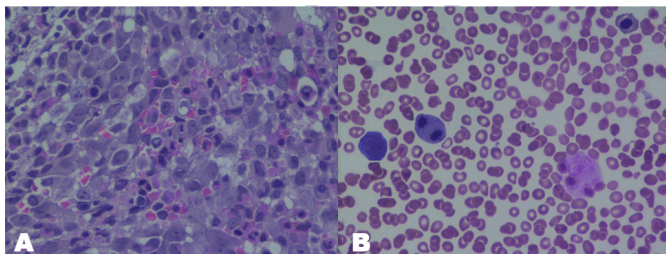


Figure 2: Trephine biopsy, H & E staining, 50x, aggregate of proerythroblasts and maturation arrest. (A) Bone marrow aspirate, Giemsa stain, 500x, Dysplastic erythroid precursors with Nuclear contour irregularities, defective hemoglobinization of cytoplasm and a mitotic figure (B).

two fusion (unrearranged) signals by FISH. These MLL rearrangements could be delineated by further molecular studies but this was not performed on our patient.

At this point the patient was diagnosed to have combined vitamin B12 deficiency and a myelodysplastic syndrome. The diagnosis of myelodysplastic syndrome, unclassified (MDS-U) was made in view of pancytopenia associated with significant dysplasia in only one lineage (erythroid) and the cytogenetic abnormality. A recommendation for clinical follow-up was made. The patient was seen in the outpatient clinic at yearly intervals and blood counts were performed.

After six months periodic follow-up was done and initial diagnosis the blood counts were found to be normal. The patient was last seen two and half years after initial diagnosis and had blood counts within reference range.

DISCUSSION

To the best of our knowledge there is no case report of

this combination of case of nutritional B12 deficiency and MDS, although one case with autoimmune pernicious anemia associated with trilineage dysplasia and genetic abnormalities has been reported [3]. The non-involvement of MLL gene was interpreted to be either a clonal abnormality associated with a hematologic disorder or a rare occurrence of cryptic MLL gene rearrangement [12]. Another similar yet distinct case of patient treated with chlorambucil for the treatment of renal amyloidosis secondary to rheumatoid arthritis presented at first with MBA with transient response to parenteral B12 therapy and then took a course of refractory anemia with excess blasts in transformation [13].

There is overlap in the clinical and pathologic features between MBA & MDS. As our patient had clinically proven low levels of serum cobalamin and in view of studies inferring that the bone marrow examination is rarely necessary or useful in the patients with macrocytosis and laboratory proven low cobalamin level [14] bone marrow examination was not performed at this stage. Persistence of pancytopenia prompted a bone marrow examination. A hypercellular marrow with significant erythroid lineage dysplasia (coupled with dysplastic changes in less than 10% megakaryocytes) was detected along with a cytogenetic abnormality leading to a diagnosis of myelodysplastic syndrome –unclassified (MDS-U), according to the WHO 2008 classification [2].

Bi/pancytopenia can occasionally be seen with MBA while unilineage dysplasia is a well-known finding in MDS cases [2]. Moreover, in MDS some of the more common abnormalities include megaloblastoid erythroid precursors resembling those seen in megaloblastic anemias [15]. While a bone marrow examination of MBA may reveal erythroid islands composed of early megaloblasts these may sometimes be mistaken for ‘abnormal localization of immature precursors’ in MDS [16]. Further, some cytogenetic abnormalities, mostly reversible, have been observed in MBA cases [17, 18] and rarely may become established as soil for future development of MDS [19], especially in view of increased risk of myeloid leukemias in patients with pernicious anemia [20, 21]. Nonetheless careful and thorough clinicopathological examination combined with necessary cytogenetic and flow cytometric studies prove fairly efficient in diagnosing MDS, as in this case. The role of bone marrow examination is pivotal. Because of its invasive nature bone marrow needs to be obtained only if clinically indicated. Clinical pointers suggesting that bone marrow examination is required along with cobalamin levels include splenomegaly, unexplained lymphadenopathy, constitutional symptoms, a history of chemotherapy or exposure to ionizing radiation. Laboratory features suggesting a bone marrow examination include, oval macrocytosis in the absence of nutritional deficiencies, chronic alcoholism, or exposure to drugs, relative or absolute monocytosis, basophilia, appearance of atypical cells on the peripheral blood smear [7].

CONCLUSION

Our findings suggest that a high index of clinical suspicion must be maintained in the workup of patients who present with pancytopenia and who are found to have B12 deficiency, where after treatment either pancytopenia persists or there are features suggesting an additional pathologic process (e.g., splenomegaly).

REFERENCES

- Hoffbrand AV. Megaloblastic anemia. In: Hoffbrand AV, Higgs DR, Keeling DM, Mehta AB, editors. *Postgraduate Haematology*. 7ed. Oxford UK: Wiley-Blackwell; 2006. p. 53–71.
- Brunning RD, Orazi A, Germing U, et al. Myelodysplastic syndromes/neoplasms, overview. In: Swerdlow SH, Campo E, Harris NL, et al. editors. *WHO Classification of Tumours of Haematopoietic and Lymphoid Tissues*. volume 2. Lyon, France: IARC Press; 2008. p. 87–107.
- Drabick JJ, Davis BJ, Byrd JC. Concurrent pernicious anemia and myelodysplastic syndrome. *Ann Hematol* 2001;80(4):243–5.
- Allen LH. How common is vitamin B-12 deficiency? *Am J Clin Nutr* 2009;89(2):693S–6S.
- Oscier DG. The Myelodysplastic syndromes. In: Provan D, editor. *ABC of Clinical Haematology*. 2ed. London: BMJ Publishing Group; 2003. p. 33–6.
- Bowen D, Culligan D, Jowitt S, et al. Guidelines for the diagnosis and therapy of adult myelodysplastic syndromes. *Br J Haematol* 2003;120(2):187–200.
- Steensma D, Tefferi A. Anemia in the elderly: How should we define it, when does it matter, and what can be done? *Mayo Clin Proc* 2007;82(8):958–66.
- Beloosesky Y, Cohen AM, Grosman B, Grinblat J. Prevalence and survival of myelodysplastic syndrome of the refractory anemia type in hospitalized cognitively different geriatric patients. *Gerontology* 2000;46(6):323–7.
- Weinzierl EP, Arber DA. The differential diagnosis and bone marrow evaluation of new-onset pancytopenia. *Am J Clin Pathol* 2013;139(1):9–29.
- Andrès E, Affenberger S, Zimmer J, et al. Current hematological findings in cobalamin deficiency. A study of 201 consecutive patients with documented cobalamin deficiency. *Clin Lab Haematol* 2006;28(1):50–6.
- Ishtiaq O, Baqai ZH, Anwer F, Hussain N. Patterns of pancytopenia patients in a general medical ward and a proposed diagnostic approach. *J Ayub Med coll Abbottabad* 2004;16(1):8–13.
- De Braekeleer E, Meyer C, Douet-Guilbert N, et al. Complex and Cryptic chromosomal rearrangements involving the MLL gene in acute leukemia: A study of 7 patients and review of the literature. *Blood cells Mol Dis* 2010;44(4):268–74.
- Balakrishnan C, Pathan E, Khodaiji S, Dasgupta A, Mangat G, Joshi VR. Myelodysplasia and acute myeloid leukaemia in a case of rheumatoid arthritis with secondary amyloidosis treated with chlorambucil. *J Assoc Physicians India* 2004;52:423–5.
- Snow CF. Laboratory diagnosis of Vitamin B12 and folate deficiency. *Arch Internal Med* 1999;159(12):1289–98.
- Aster JC. The hematopoietic and lymphoid system. In: Kumar V, Abbas AK, Aster J, editors. *Robbins Basic Pathology*. 9ed. Philadelphia, Pennsylvania: Elsevier; 2013. p. 421–79.
- Bain BJ, Clark DM, Lampert IA, Wilkins BS. Disorders of erythropoiesis, granulopoiesis and thrombopoiesis. In: Bain BJ, Clark DM, Lampert IA, Wilkins BS, editors. *Bone Marrow Pathology*. 3ed. Oxford, USA: Blackwell Sciences Ltd; 2006. p. 360–90.
- Chintagumpala MM, Dreyer ZE, Steuber CP, Cooley LD. Pancytopenia with chromosomal fragility; vitamin B12 deficiency. *J Pediatr Hematol Oncol* 1996;18(2):166–70.
- Wollman MR, PENCHANSKY L, SHEKHTER-LEVIN S. Transient 7q- in association with megaloblastic anemia due to dietary folate and Vitamin B12 deficiency. *J Pediatr Hematol Oncol* 1996;18(2):162–5.
- Cohen HJ. Biology of aging as related to cancer. *Cancer* 1994;74(7 Suppl):2092–100.
- Blackburn EK, Callender ST, Dacie JV, et al. Possible association between pernicious anemia and leukaemia: A prospective study of 1625 patients with a note on the very high incidence of stomach cancer. *Int J Cancer* 1968;3(1):163–70.
- Hsing AW, Hansson LE, McLaughlin JK, et al. Pernicious Anemia and subsequent cancer. Population-based cohort study. *Cancer* 1993;71(3):745–50.

Author Contributions

Amal Khan – Substantial contributions to conception and design, Acquisition of data, Analysis and interpretation of data, Drafting the article, Revising it critically for important intellectual content, Final approval of the version to be published

Adel Bensaleh – Substantial contributions to conception and design, Analysis and interpretation of data, Revising it critically for important intellectual content, Final approval of the version to be published

Anurag Saxena – Substantial contributions to conception and design, Acquisition of data, Analysis and interpretation of data, Drafting the article, Revising it critically for important intellectual content, Final approval of the version to be published

Guarantor of Submission

The corresponding author is the guarantor of submission.

Source of Support

None.

Consent Statement

Written informed consent was obtained from the patient for publication of this case report.

Conflict of Interest

Authors declare no conflict of interest.

Data Availability

All relevant data are within the paper and its Supporting Information files.

Copyright

© 2018 Amal Khan et al. This article is distributed under the terms of Creative Commons Attribution License which permits unrestricted use, distribution and reproduction in any medium provided the original author(s) and original publisher are properly credited. Please see the copyright policy on the journal website for more information.

Access full text article on
other devices



Access PDF of article on
other devices

