

# Mixed diffuse angiomatosis/lymphangiomatosis of the breast in SLE patient: An unusual case report and literature review

Zahra Al-Turaifi, Tarek El Sharkawy, Maha Abdel-Hadi,  
Afnan Al-Muhana, Sara Al Brieki

## ABSTRACT

**Introduction:** Angiomatosis/lymphangiomatosis is a rare, reactive angioproliferative lesion in the skin and is considered to be a subtype in the group of cutaneous reactive angiomatoses. However, few cases of diffuse dermal angiomatosis of the breast (DDAB) have been reported in the literature. **Case Report:** In this case report, we present a patient known to have systemic lupus erythematosus (SLE) with mixed diffuse angiomatosis/lymphangiomatosis of both breasts mimicking inflammatory carcinoma. We describe the clinical and histopathologic characteristics, pathogenetic mechanisms, and predisposing risk factors of this rare skin disorder and discuss treatment options. **Conclusion:** Currently, there is no agreement on the best therapeutic approach. Isotretinoin and

other medical therapies have been used with limited success. Laser therapy and breast reduction appears to be a reliable treatment option for DDAB and might provide definitive treatment.

**Keywords:** Angiomatosis, Breast, Lymphangiomatosis, SLE

### How to cite this article

Al-Turaifi Z, El Sharkawy T, Abdel-Hadi M, Al-Muhana A, Al Brieki S. Mixed diffuse angiomatosis/lymphangiomatosis of the breast in SLE patient: An unusual case report and literature review. J Case Rep Images Pathol 2020;6:100035Z11ZA2020.

Article ID: 100035Z11ZA2020

\*\*\*\*\*

doi: 10.5348/100035Z11ZA2020CR

Zahra Al-Turaifi<sup>1</sup>, Tarek El Sharkawy<sup>2</sup>, Maha Abdel-Hadi<sup>3</sup>,  
Afnan Al-Muhana<sup>4</sup>, Sara Al Brieki<sup>5</sup>

**Affiliations:** <sup>1</sup>Resident, Department of Pathology, Imam Abdulrahman Bin Faisal University, King Fahad University Hospital, Al Khobar, Eastern Province, Saudi Arabia; <sup>2</sup>Associate Professor, Department of Pathology, Imam Abdulrahman Bin Faisal University, King Fahad University Hospital, Al Khobar, Eastern Province, Saudi Arabia; <sup>3</sup>Professor, Department of Surgery, Imam Abdulrahman Bin Faisal University, King Fahad University Hospital, Al Khobar, Eastern Province, Saudi Arabia; <sup>4</sup>Assistant Professor, Department of Radiology, Imam Abdulrahman Bin Faisal University, King Fahad University Hospital, Al Khobar, Eastern Province, Saudi Arabia; <sup>5</sup>Assistant Professor, Department of Dermatology, Imam Abdulrahman Bin Faisal University, King Fahad University Hospital, Al Khobar, Eastern Province, Saudi Arabia.

**Corresponding Author:** Tarek El Sharkawy, King Fahd Hospital, Accommodation (Site1), Alaqrabiyah 2916, Unit 134, Khobar 34446, Eastern Province, Saudi Arabia; Email: tel-sharkawy@iau.edu.sa

Received: 24 April 2020

Accepted: 04 July 2020

Published: 27 July 2020

## INTRODUCTION

Mammary angiomatosis is a rare, benign vascular lesion that morphologically mimics inflammatory carcinoma. The purpose of this case report study was to further characterize mammary angiomatosis by clinical, histological, and immunohistochemical means while emphasizing distinguishing features from different pathological lesions.

## CASE REPORT

A 31-year-old woman with a known history of systemic lupus erythematosus presented with a slow onset of symptoms that have developed within one year. Bilateral painful mammary erythema and edema, with no palpable

mass, typically involve two-thirds or more of both breasts. Clinically there is *peau d'orange*, a French term meaning “skin of an orange” that describes the pitted, dimpling skin. Both breasts are enlarged, warm, and tender, which are symptoms that mimic inflammatory breast carcinoma (Figure 1).

The risk of inflammatory breast carcinoma was raised, which was aided by magnetic resonance imaging (MRI) and ultrasonographic evaluation demonstrating patchy areas of skin thickening with hyperenhancement post-gadolinium administration, no primary breast lesion was detected (Figure 2).

Histopathological examination reveals a proliferation of bland spindle endothelial cells involving the reticular dermis and extending to superficial panniculus in a patchy distribution. The lesion displays compactly arranged cells without atypia or significant mitosis. No extravasated erythrocytes identified. These endothelial cells are forming a thin wall, variable-sized lumina dissecting between dermal collagen bundles. There was no evidence of vasculitis, thrombotic vasculopathy, or papillary endothelial hyperplasia (Figure 3A and B).

Immunohistochemically, CD31 was diffusely positive in both hemangiomatous and lymphangiomatous appearing vessels, while the latter vessels were also reactive for D2-40.

Cytokeratin was negative ruling out inflammatory breast carcinoma. Staining for (HHV-8) was negative. Special stains of Grocott's methenamine-silver (GMS) and periodic acid–Schiff (PAS) show no reactivity for infectious organisms. Angiosarcoma was ruled out by the absence of atypia and mitosis and a lack of history of prior radiation. Based on histopathologic findings and the patient's history, mixed diffuse angiomatosis/lymphangiomatosis was justified (Figure 3C–F).

The case was discussed extensively in the multidisciplinary meeting in our institution and the outlined treatment plan included: trial of local steroid ointments and antibiotics for the occasional skin infection. These trials ended by minimal response.

Then laser therapy to the affected area was also attempted with no satisfactory relief of the patient's symptoms. The consensus was to perform a limited mammoplasty and total excision of the affected area with the patient's full understanding that this procedure may need to be revised in case the condition recurs.

## DISCUSSION

Diffuse dermal angiomatosis (DDA) is a rare cutaneous vascular disorder described initially as an entity of reactive angioendotheliomatosis in 1994 [1]. Breast involvement by DDA has been reported for a total of 45 published cases in literature with the largest series consisting of 22 patients [2]. In contrast, lymphangiomatosis is a diffuse lymphangiomatous lesion. It is miscommunication between lymphatic and venous channels that more

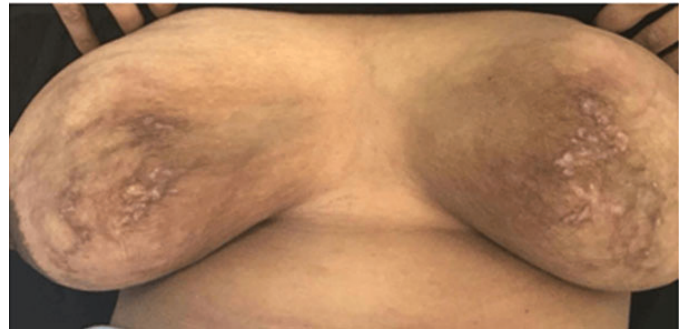


Figure 1: Bilateral mammary lesion composed of epidermal purpuric patches and indurated plaques with prominent congested blood vessels, complicated by tender shallow ulceration.

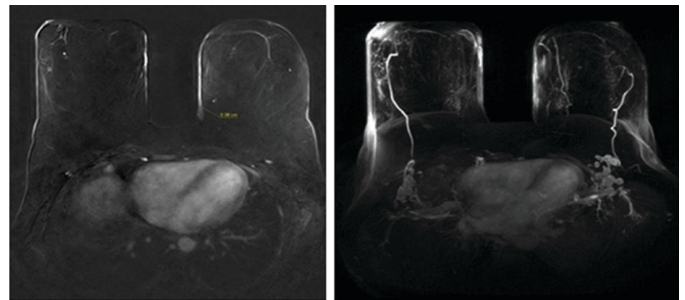


Figure 2: Contrast-enhanced MRI and MIP images revealed a patchy area of skin thickening and hyperenhancement at both lower medial breasts more pronounced at left lower medial posterior breast with a maximum thickness of 0.38 cm.

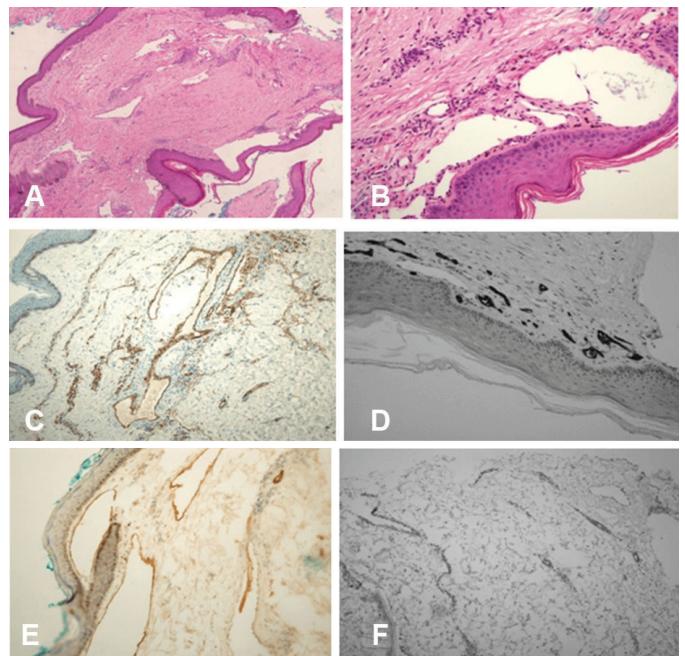


Figure 3: (A and B) H&E section ( $\times 40$  and  $\times 200$ ) demonstrating endothelial proliferative channels involving papillary and reticular dermis with small to medium variable-sized lumina. (C) CD31 immunohistochemistry highlighting the formation of small lumens between dermal collagen bundles. (D) Strong expression of CD34 for hemangiomatous—appearing. (E) Positive D2-40 in lymphatic channels. (F) Negative HHV-8 in endothelial blood vessels.

commonly occurs in utero rather than late presentation [3].

Diffuse dermal angiomatosis clinically presented as slow growing, reticulated erythematous to violaceous or purpuric patches and indurated plaques with vessels prominence, complicated by tender shallow ulceration. The pathogenesis of DDA is incompletely explained, but the attribute consequences is most likely produced by ischemia and tissue hypoxia due to partially occlusive or inflammatory vascular process. New vessels are increasing to restore diminished blood circulation and tissue oxygenation. A wide scope of predisposing comorbidities has been associated with DDA, such as atherosclerosis [4], iatrogenic arteriovenous malformation [5], monoclonal gammopathy [6], a hypercoagulopathy state in antiphospholipid syndrome [7]. The most predisposing conditions for DDA were large pendulous breast, obesity, and smoking.

While lymphangiomatosis usually develops as acute incidence following blockage of thoracic lymph duct leading to the development of ascites, chylothorax, and redundant hyperpigmented skin.

Pathologically, it is the presence of both hemangiomas—appearing [contains extravasated red blood cell (RBC) and hemosiderin] and lymphangiomatous—appearing (empty or containing lymph) channels with an absence of smooth muscle around the vessels. These channels are lined by flat, endothelial cells that infiltrate mammary stroma and adipose tissue and display diffuse, perilobular, and extralobular growth. Ancillary studies are used to confirm the normal endothelial phenotypic of cells lining the blood channels. Positivity is found for vascular markers (CD31 and CD34) and SMA- $\alpha$ . D2-40, a marker of lymphatic endothelium, is typically positive in lymphatic spaces. This gives us a clue that this case is mixed diffuse angiomatosis/lymphangiomatosis.

The vascular tumors of mammary origin are extremely rare, and the majority of them are malignant. The vascular lesions of the breast include hemangioma, perilobular hemangioma, pseudoangiomatous stromal hyperplasia, Kaposi sarcoma (KS), and angiosarcoma [8].

Hemangioma is a benign vascular lesion. It is composed of well-circumscribed, cavernous spaces. It does not invade or destroy the lobule but may change the surrounding tissue. Papillae or tufting can be seen while atypia, hemorrhage, and necrosis are absent [9].

Perilobular hemangioma is composed of vascular channels that range from capillary to cavernous vessels. This is an incidental finding that occurs within the lobular stroma or in the extralobular stroma. There are no atypia, papillae, or mitosis [9].

Pseudoangiomatous stromal hyperplasia (PASH) shows anastomosing pseudovascular slit-like spaces in collagen bundles without true vascular lining or extravasated RBC. These show variable cellularity with dense hyalinized collagen bundles [10].

Kaposi sarcoma has variants of histological features, including spindle cell with atypia, diffuse slit-like lumen, and formation with promontory sign and inflammatory compartments. These findings supported by the positivity of CD31, CD34, and HHV8.

The discrimination between angiomatosis and low-grade angiosarcoma (LGAS) is of great importance due to the high impact of differences in prognosis and treatment. Both angiomatosis and LGAS demonstrate anastomosing blood vessels that show diffuse, perilobular growth. However, LGAS diagnostic features include the destruction of the lobules and histomorphological finding of endothelial atypia, nuclear hyperchromasia, and infrequent mitosis. Neither of the vascular markers would be helpful in distinguishing angiomatosis from LGAS. Also, D2-40 can be expressed in a few cases of angiosarcoma [10]. Low-grade angiosarcoma shows an increased Ki-67 proliferation index (typically >20%) in comparison to angiomatosis with low Ki-67 proliferation index (<5%) [11–13].

Ulceration is a common complication of DDA due to newly developed superficial blood vessels through the skin. The recommendation for treatment is focused on smoking cessation and control of cardiovascular risk factors. Medical treatment includes isotretinoin, acetylsalicylic acid, and oral steroid [8].

Surgical management of DDA of the breast includes excisional biopsy as adequate therapy for mammary angiomatosis. However, simple mastectomy sometimes is needed due to the diffuse nature of this disease. Re-excision is indicated for incompletely excised tumors due to the risk of local recurrence, but it has not known to metastasize [4].

## CONCLUSION

Angiomatosis/lymphangiomatosis is a rare, reactive angioproliferative lesion in the skin and is considered to be a subtype in the group of cutaneous reactive angiomatoses. However, few cases of DDAB have been reported in the literature. Currently, there is no agreement on the best therapeutic approach. Isotretinoin and other medical therapies have been used with limited success. Laser therapy and breast reduction appears to be a reliable treatment option for DDAB and might provide definitive treatment.

## REFERENCES

1. Krell JM, Sanchez RL, Solomon AR. Diffuse dermal angiomatosis: A variant of reactive cutaneous angioendotheliomatosis. *J Cutan Pathol* 1994;21(4):363–70.
2. Reusche R, Winocour S, Degnim A, Lemaine V. Diffuse dermal angiomatosis of the breast: A series of 22 cases from a single institution. *Gland Surg* 2015;4(6):554–60.

3. Hynes SO, McLaughlin R, Kerin M, Rowaiye B, Connolly CE. A unique cause of a rare disorder, unilateral macromastia due to lymphangiomatosis of the breast: A case report. *Breast J* 2012;18(4):367–70.
4. Kimyai-Asadi A, Nousari HC, Ketabchi N, Henneberry JM, Costarangos C. Diffuse dermal angiomatosis: A variant of reactive angioendotheliomatosis associated with atherosclerosis. *J Am Acad Dermatol* 1999;40(2 Pt 1):257–9.
5. Requena L, Fariña MC, Renedo G, Alvarez A, Yus ES, Sanguenza OP. Intravascular and diffuse dermal reactive angioendotheliomatosis secondary to iatrogenic arteriovenous fistulas. *J Cutan Pathol* 1999;26(3):159–64.
6. Tollefson MM, McEvoy MT, Torgerson RR, Bridges AG. Diffuse dermal angiomatosis of the breast: clinicopathologic study of 5 patients. *J Am Acad Dermatol* 2014;71(6):1212–7.
7. Pichardo RO, Lu D, Sanguenza OP, Guitart J. What is your diagnosis? Diffuse dermal angiomatosis secondary to antitricardiolipin antibodies. *Am J Dermatopathol* 2002;24(6):502–3.
8. Rosen PP. Vascular tumors of the breast. III. Angiomatosis. *Am J Surg Pathol* 1985;9(9):652–8.
9. Jozefczyk MA, Rosen PP. Vascular tumors of the breast. II. Perilobular hemangiomas and hemangiomas. *Am J Surg Pathol* 1985;9(7):491–503.
10. Fukunaga M. Expression of D2-40 in lymphatic endothelium of normal tissues and in vascular tumours. *Histopathology* 2005;46(4):396–402.
11. Frey JD, Levine PG, Darvishian F, Shapiro RL. Angiosarcoma of the breast masquerading as hemangioma: Exploring clinical and pathological diagnostic challenges. *Arch Plast Surg* 2015;42(2):261–3.
12. McLaughlin ER, Morris R, Weiss SW, Arbiser JL. Diffuse dermal angiomatosis of the breast: Response to isotretinoin. *J Am Acad Dermatol* 2001;45(3):462–5.
13. Ginter PS, McIntire PJ, Irshaid L, Liu YF, Shin SJ. Angiomatosis of the breast: A clinicopathological and immunophenotypical characterisation of seven cases. *J Clin Pathol* 2019;72(9):597–602.

\*\*\*\*\*

### Author Contributions

Zahra Al-Turaifi – Conception of the work, Acquisition of data, Interpretation of data, Drafting the work, Final approval of the version to be published, Agree to be accountable for all aspects of the work in ensuring that questions related to the accuracy or integrity of any part of the work are appropriately investigated and resolved

Tarek El Sharkawy – Conception of the work, Design of the work, Analysis of data, Interpretation of data, Revising

the work critically for important intellectual content, Final approval of the version to be published, Agree to be accountable for all aspects of the work in ensuring that questions related to the accuracy or integrity of any part of the work are appropriately investigated and resolved

Maha Abdel-Hadi – Conception of the work, Revising the work critically for important intellectual content, Final approval of the version to be published, Agree to be accountable for all aspects of the work in ensuring that questions related to the accuracy or integrity of any part of the work are appropriately investigated and resolved

Afnan Al-Muhana – Acquisition of data, Analysis of data, Revising the work critically for important intellectual content, Final approval of the version to be published, Agree to be accountable for all aspects of the work in ensuring that questions related to the accuracy or integrity of any part of the work are appropriately investigated and resolved

Sara Al Brieki – Acquisition of data, Analysis of data, Revising the work critically for important intellectual content, Final approval of the version to be published, Agree to be accountable for all aspects of the work in ensuring that questions related to the accuracy or integrity of any part of the work are appropriately investigated and resolved

### Guarantor of Submission

The corresponding author is the guarantor of submission.

### Source of Support

None.

### Consent Statement

Written informed consent was obtained from the patient for publication of this article.

### Conflict of Interest

Authors declare no conflict of interest.

### Data Availability

All relevant data are within the paper and its Supporting Information files.

### Copyright

© 2020 Zahra Al-Turaifi et al. This article is distributed under the terms of Creative Commons Attribution License which permits unrestricted use, distribution and reproduction in any medium provided the original author(s) and original publisher are properly credited. Please see the copyright policy on the journal website for more information.

Access full text article on  
other devices



Access PDF of article on  
other devices



**Submit your manuscripts at**  
[www.edoriumjournals.com](http://www.edoriumjournals.com)