

Intradermal nodular fasciitis of the ear auricle: A case report and literature review

Ahmed Shah, Samih Salama, Gabriella Gohla, Salem Alowami

ABSTRACT

Introduction: Nodular fasciitis (NF) is a benign self-limited neoplasm of fibroblastic and myofibroblastic derivation. It primarily arises within the subcutaneous tissue. It arises less frequently in the skeletal muscle, and very rarely in the skin. Nodular fasciitis of the ear is very rare with only seven publications including one case series of 50 cases, of which only 6 arising from the auricle or pinna are reported in total. Moreover, intradermal NF is itself an extremely rare entity with only 36 reported cases in literature. **Case Report:** We report a case of a 53-year-old man who presented with a tender oval-shaped intradermal lesion of the right ear that developed over several weeks, which after histological and immunohistochemical analysis was diagnosed as NF. Our differential diagnoses for NF is atypical fibroxanthoma (AFX) and sarcomas. Other mimics include melanoma, poorly differentiated squamous cell carcinoma, all of which were excluded by the immunohistochemistry analysis. PUBMED database was used to search for available literature on NF of the ear and intradermal NF. **Conclusion:** Nodular fasciitis should be distinguished from AFX, sarcomas, melanoma, and squamous cell carcinoma due to significantly different clinical outcomes. The diagnosis is dependent on morphology and distinct immunohistochemistry staining pattern. Complete excision is standard of practice for symptom management and to exclude other differential diagnoses.

Ahmed Shah¹, Samih Salama^{1,2}, Gabriella Gohla^{1,2}, Salem Alowami^{1,2}

Affiliations: ¹Department of Pathology and Molecular Medicine, McMaster University, 1280 Main Street West, Hamilton, Ontario, Canada; ²Department of Pathology and Molecular Medicine, St. Joseph's Hospital, 2757 King Street East, Hamilton, Ontario, Canada.

Corresponding Author: Dr. Ahmed Shah, Department of Pathology and Molecular Medicine, McMaster University, 1280 Main Street West, Hamilton, Ontario, Canada; Email: ahmed.shah@medportal.ca

Received: 21 May 2020

Accepted: 13 July 2020

Published: 10 September 2020

Keywords: Atypical fibroxanthoma, Ear, Nodular fasciitis, Sarcoma

How to cite this article

Shah A, Salama S, Gohla G, Alowami S. Intradermal nodular fasciitis of the ear auricle: A case report and literature review. J Case Rep Images Pathol 2020;6:100038Z11AS2020.

Article ID: 100038Z11AS2020

doi: 10.5348/100038Z11AS2020CR

INTRODUCTION

Nodular fasciitis (NF) is a benign self-limited neoplasm of fibroblastic and myofibroblastic derivation. It primarily arises within the subcutaneous tissue. It arises less frequently in the skeletal muscle, and very rarely in the skin. Due to its rapid growth, high cellularity, and mitotic activity, NF can be confused with malignant lesions. Histologically, NF involving the skin needs to be distinguished from several entities including atypical fibroxanthoma (AFX), sarcomas, melanoma, and squamous cell carcinoma, all of which have vastly different clinical managements. Nodular fasciitis has propensity to occur in children and young adults on head and neck, trunk and upper extremities, but it is extremely rare to occur in the auricular region. Its etiology was thought to be reactive, but it is now found to have USP6-MYH9 fusion gene in most cases, thus favoring a neoplastic process.

In this study, we will discuss a case of intradermal NF in the pinna of a middle-aged man, which is a very rare presentation. The purpose of this paper is to broaden the clinical differential of post-auricular lesions of the skin and provide a succinct histological and immunohistochemical guide to distinguish NF from other more common clinical and pathologic mimickers.

CASE REPORT

A 53-year-old man presented with a tender oval-shaped lesion of the right posterior auricular region that developed over several weeks. The computed tomography (CT) scan revealed hyperdense well-defined oval-shaped structure in the external ear inseparable from the skin measuring $1.9 \times 1.8 \times 1.4$ cm with no bony erosion or destruction of the underlying mastoid bone, which was separated from the lesion with a fat plane. Moreover, there were no lymphadenopathy or any other suspicious soft tissue or osseous lesion. The histology revealed atypical spindle cell neoplasm with fascicular arrangement with occasional epithelioid cells and multinucleated giant cells involving the superficial and deep dermis (Figure 1). The lesional cells showed variable degrees of nuclear pleomorphism with occasional mitoses, approximately 7 per 10 high-power fields (HPF) (Figure 1C). The lesion showed slight-to-moderate fibrotic stroma, which was seen expanding the superficial and deep dermis. Immunohistochemistry was positive for vimentin, CD10, CD99, alpha smooth muscle antigen, B-catenin, and focal positivity for D2-40 (Figure 2). Ki-67 proliferation showed 10% of nuclear expression. Immunohistochemistry was negative for S100, PAN-ME, HMB45, muscle-specific actin (MSA), desmin, myosin, CD34, MCK, CAM5.2, epithelial membrane antigen (EMA), p63, CD31, ALK1, HHV8. The histological and immunohistochemistry findings were consistent with the diagnosis of NF.

DISCUSSION

Nodular fasciitis is a benign solitary, circumscribed, subcutaneous nodule that affects adult males and females equally [1]. Although NF grows rapidly over several weeks,

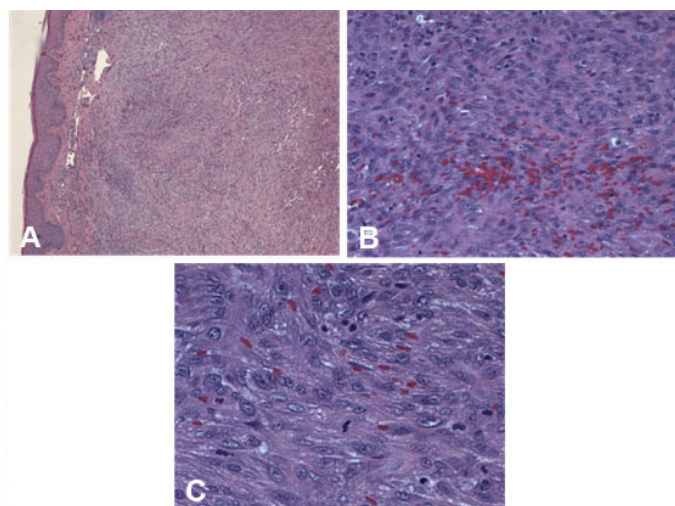


Figure 1: Representative morphological images of intradermal nodular fasciitis of the ear auricle. (A) Tumor involvement in the dermis, H&E staining, $\times 40$ magnification. (B) Spindle cell neoplasm with slight fibrotic stroma, H&E staining, $\times 200$ magnification. (C) Tumor cell with mitoses, H&E staining, $\times 400$ magnification.

it usually presents smaller than 2 cm in size [2, 3]. The dermal variant of NF is very rare and can present with additional symptoms of pain [4]. In our case, the patient presented with tenderness. The most common sites for NF occurrence are the upper extremities, especially the forearm, followed by the trunk, and head and neck [5]. Nodular fasciitis of the ear auricle or pinna is very rare. In a case series of 50 patients on NF of the ear region, only 2 patients or 4% were of the pinna [3]. Based on our literature search, only 8 cases of auricular NF have

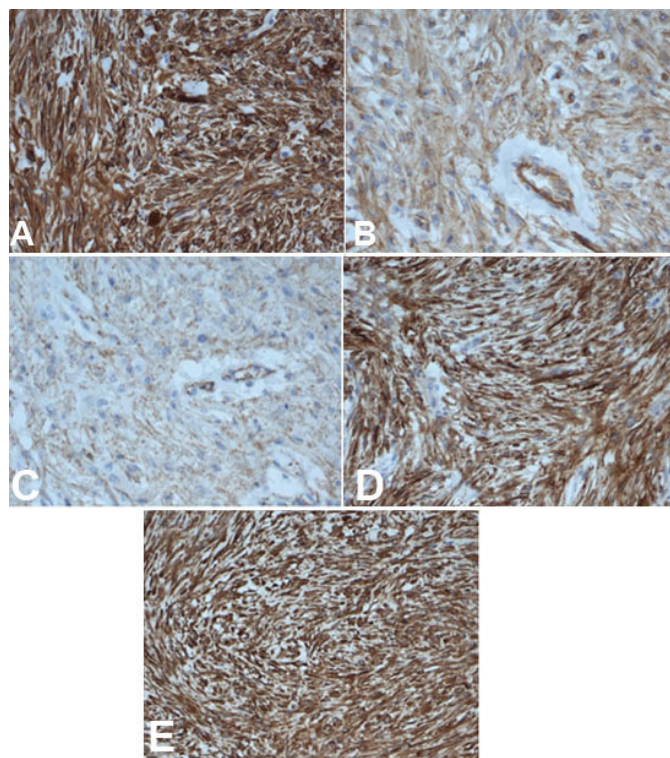


Figure 2: Representative images of positive immunohistochemistry staining of intradermal nodular fasciitis of the ear auricle. (A) CD10, $\times 200$ magnification. (B) CD99, $\times 200$ magnification. (C) Beta-catenin, $\times 200$ magnification. (D) SMA, $\times 200$ magnification. (E) Vimentin, $\times 200$ magnification.

been reported (Table 1). All the cases reported thus far and including this case, the average age of patients with auricular NF is 35.1 years and this affects males 85.7% of the time. Interestingly, auricular NF involves the dermis in most cases with subcutaneous involvement reported only in two cases (Table 1). Intradermal NF is itself a rare entity with only 36 cases reported in literature, of which 5 cases are from the ear auricle. Like subcutaneous NF, the dermal variant also seldom presents greater than 2 cm in size (Tables 1 and 2).

Nodular fasciitis was first described in 1955 by Konwaler et al., as subcutaneous pseudosarcomatous fibromatosis due to its ability to mimic sarcomas histologically [15]. Clinically, dermatofibroma, lipoma, neuroma, and fibrosarcoma are often parts of the differential diagnoses [16]. Microscopically, the lesion was a spindle cell neoplasm with atypical spindle cell density

Table 1: Clinical presentation of auricular nodular fasciitis reported in literature

Sex	Location	Age	Size (mean)	Number of cases	Reference
Male	Not available	“Young male”	Not available	1	[6]
Male	Dermis	16	1.5 cm	1	[7]
Male	Dermis	45	0.7 cm	1	[8]
Female	Dermis	25	2 cm	1	[9]
Not available	Dermis	Not available	2.3 cm	2	[3]
Male	Dermis and subcutaneous	19	1.7 cm	1	[10]
Male	Subcutaneous	53	2 cm	1	[11]
Male	Dermis	53	1.9 cm	1	This case

Table 2: Clinical presentation of extra-auricular intradermal nodular fasciitis

Sex	Site	Age (mean)	Size (mean)	Number of cases	Reference
Male	Eyelid	26	1.0 cm	1	[12]
Female	Face	41	0.5 cm	1	[1]
Male	Arm	37	0.42 cm	1	[13]
Male (10) Female (14)	6 head and neck, 9 limbs, 9 trunk	27.5	1.96 cm	24	[2]
Male (1) Female (2)	1 scalp, 1 cheek 1 medial canthus	31.3	0.83 cm	3	[4]
Not available	Not available	Not available	Not available	1	[14]

and extravasated erythrocytes (Figure 1B). Therefore, our differential diagnoses for NF included AFX, spindle cell melanoma, poorly differentiated squamous cell carcinoma, and sarcomas such as dermatofibrosarcoma protuberans (DFSP) and nodular stage of Kaposi sarcoma (KS). Furthermore, the immunohistochemistry showed positive expression with vimentin, CD10, CD99, alpha smooth muscle antigen (aSMA), and negative expression for S100, HMB45, MSA, desmin, CD34, MCK, CAM5.2, EMA, CD31, ALK1, and HHV8. Therefore, mimics including melanoma, and poorly differentiated squamous cell carcinoma were sufficiently excluded. Furthermore, CD34 and HHV8 staining sufficiently excluded DFSP and KS, respectively.

Overall, the features were suggestive of atypical fibrohistiocytic proliferation with the diagnosis consistent with NF and the differential diagnosis of AFX and pleomorphic sarcoma. Although this lesion showed atypical spindle cells with variable pleomorphism and mitoses, there was no necrosis, ulceration, lymphovascular invasion, or perineural involvement that would make it suspicious for a malignant process. Furthermore, the patient’s young age and lack of bizarre-appearing and highly atypical epithelioid cells made the diagnosis of AFX unlikely, which largely occurs in patients above the age of 70 years [17].

Although auricular intradermal NF is a very rare entity, but pathologists and clinicians should be aware to

include it as part of the differential diagnosis for rapidly growing dermal nodules of the ear. It may initially appear ominous for malignancy both clinically and histologically, so careful analysis of clinical history and risk factors, supplemented by histological and immunohistochemical workup is essential to reach the correct diagnosis.

CONCLUSION

Intradermal auricular NF is extremely rare entity. It should be distinguished from AFX, sarcomas, melanoma, and squamous cell carcinoma due to significantly different clinical outcomes. The diagnosis is dependent on morphology and distinct immunohistochemistry staining pattern. Complete excision is standard of practice for symptom management and to exclude other differential diagnoses.

REFERENCES

1. Kang SK, Kim HH, Ahn SJ, et al. Intradermal nodular fasciitis of the face. *J Dermatol* 2002;29(5):310–4.
2. de Feraudy S, Fletcher CDM. Intradermal nodular fasciitis: A rare lesion analyzed in a series of 24 cases. *Am J Surg Pathol* 2010;34(9):1377–81.

3. Thompson LD, Fanburg-Smith JC, Wenig BM. Nodular fasciitis of the external ear region: A clinicopathologic study of 50 cases. *Ann Diagn Pathol* 2001;5(4):191–8.
4. Nishi SPE, Brey NV, Sanchez RL. Dermal nodular fasciitis: Three case reports of the head and neck and literature review. *J Cutan Pathol* 2006;33(5):378–82.
5. Shimizu S, Hashimoto H, Enjoji M. Nodular fasciitis: An analysis of 250 patients. *Pathology* 1984;16(2):161–6.
6. Lu Y, Feng Y, Xu J. Nodular fasciitis of external ear: A case report. [Article in Chinese]. *Lin Chung Er Bi Yan Hou Tou Jing Wai Ke Za Zhi* 2012;26(16):762–3.
7. Jain D, Khurana N, Jain S. Nodular fasciitis of the external ear masquerading as pleomorphic adenoma: A potential diagnostic pitfall in fine needle aspiration cytology. *Cytojournal* 2008;5:14.
8. Elsensohn A, Getty S, Shiu J, de Feraudy S. Intradermal proliferative fasciitis occurring with chondrodermatitis nodularis helices. *Am J Dermatopathol* 2018;40(2):139–41.
9. Majidi MR, Jafarian AH, Irani S. Nodular fasciitis of the auricle: A case report. *Iran J Otorhinolaryngol* 2013;25(71):115–8.
10. Ahn J, Kim S, Park Y. Nodular fasciitis of external auditory canal. *J Pathol Transl Med* 2016;50(5):394–6.
11. Katahashi T, Shimada F, Omura K, Makino S, Matsuzaki O. A case of nodular fasciitis arising in the auricle. *Auris Nasus Larynx* 1995;22(1):59–64.
12. Meffert JJ, Kennard CD, Davis TL, Quinn BD. Intradermal nodular fasciitis presenting as an eyelid mass. *Int J Dermatol* 1996;35(8):548–52.
13. Fujioka K, Fujioka A, Oishi M, Eto H, Tajima S, Nakayama T. Ultrasonography findings of intradermal nodular fasciitis: A rare case report and review of the literature. *Clin Exp Dermatol* 2017;42(3):335–6.
14. Terai M, Oka M, Kunisada M, Kawakami F, Nishigori C. Intradermal nodular fasciitis. *Eur J Dermatol* 2012;22(2):285–6.
15. Konwaler BE, Keasbey L, Kaplan L. Subcutaneous pseudosarcomatous fibromatosis (fasciitis). *Am J Clin Pathol* 1955;25(3):241–52.
16. Samaratunga H, Searle J, O’Loughlin B. Nodular fasciitis and related pseudosarcomatous lesions of soft tissues. *Aust N Z J Surg* 1996;66(1):22–5.
17. Mirza B, Weedon D. Atypical fibroxanthoma: A clinicopathological study of 89 cases. *Australas J Dermatol* 2005;46(4):235–8.

Author Contributions

Ahmed Shah – Conception of the work, Design of the work, Acquisition of data, Analysis of data, Interpretation of data, Drafting the work, Revising the work critically for important intellectual content, Final approval of the version to be published, Agree to be accountable for all aspects of the work in ensuring that questions related to the accuracy or integrity of any part of the work are appropriately investigated and resolved

Samih Salama – Conception of the work, Design of the work, Acquisition of data, Analysis of data, Interpretation of data, Drafting the work, Revising the work critically for important intellectual content, Final approval of the version to be published, Agree to be accountable for all aspects of the work in ensuring that questions related to the accuracy or integrity of any part of the work are appropriately investigated and resolved

Gabriella Gohla – Conception of the work, Design of the work, Acquisition of data, Analysis of data, Interpretation of data, Drafting the work, Revising the work critically for important intellectual content, Final approval of the version to be published, Agree to be accountable for all aspects of the work in ensuring that questions related to the accuracy or integrity of any part of the work are appropriately investigated and resolved

Salem Alowami – Conception of the work, Design of the work, Acquisition of data, Analysis of data, Interpretation of data, Drafting the work, Revising the work critically for important intellectual content, Final approval of the version to be published, Agree to be accountable for all aspects of the work in ensuring that questions related to the accuracy or integrity of any part of the work are appropriately investigated and resolved

Guarantor of Submission

The corresponding author is the guarantor of submission.

Source of Support

None.

Consent Statement

This case does not use any specific patient identifiers, and the pictures are of microscopic histology and immunohistochemistry that cannot be used for patient identification purposes. In the department of pathology, we do not directly interact with patients, but all efforts have been made in great detail to anonymize the case as much as possible.

Conflict of Interest

Authors declare no conflict of interest.

Data Availability

All relevant data are within the paper and its Supporting Information files.

Copyright

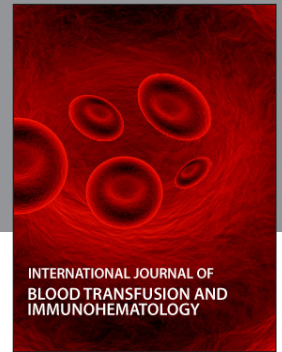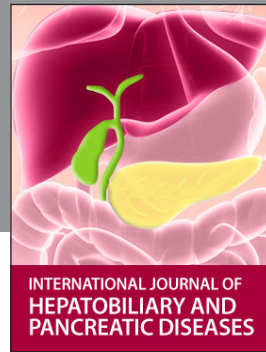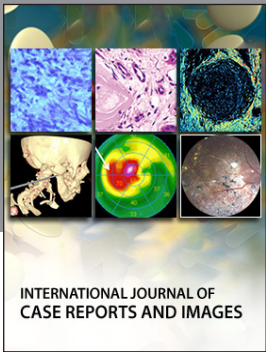
© 2020 Ahmed Shah et al. This article is distributed under the terms of Creative Commons Attribution License which permits unrestricted use, distribution and reproduction in any medium provided the original author(s) and original publisher are properly credited. Please see the copyright policy on the journal website for more information.

Access full text article on
other devices



Access PDF of article on
other devices





Submit your manuscripts at
www.edoriumjournals.com

