

# Insidious high grade serous carcinoma of a prolapsing fallopian tube

Nurfiza Ladak, Alan Marcus, Andrea Hernandez, Esther Adler

## CASE REPORT

Fallopian tube prolapse is a rare, post-hysterectomy complication that occurs when a portion of the fallopian tube prolapses into the vaginal vault. There are no previous reports of carcinoma arising in a prolapsed fallopian tube. Herein, we present a rare case of a prolapsing fallopian tube with high grade serous carcinoma.

A 42-year-old woman, status post-hysterectomy performed 16 years prior for a benign indication, presented with two months of vaginal spotting and post-coital bleeding. Cervical cytology performed nine months prior was negative for intraepithelial lesion or malignancy. On pelvic exam, she was found to have a 3 cm exophytic, irregularly shaped, cherry-red lesion protruding from the posterior vaginal cuff. A subsequent biopsy revealed fragments of fallopian tube tissue with minute foci of invasive tumor, consisting of nests of large, pleomorphic cells, with eccentric nuclei, scattered prominent nucleoli, and moderate to abundant pink cytoplasm, measuring up to 0.1 cm in greatest dimension (Figure 1). Immunohistochemical stains showed that the tumor was positive for WT-1, PAX-8, and estrogen receptor (ER), and demonstrated an aberrant, diffusely and strongly positive, pattern of p53 expression. The surrounding benign fallopian tube epithelium was

positive for PAX-8 and WT-1 and demonstrated a wild type pattern of p53 expression (Figure 1). Overall, these findings were consistent with minute foci of high grade serous carcinoma involving fragments of fallopian tube. The patient subsequently underwent a bilateral salpingo-oophorectomy and complete surgical staging which showed a single, 0.1 cm focus of high grade serous carcinoma involving the fimbriated end of the left fallopian tube (Figure 2). Pelvic washings performed at the time of surgery were negative for malignancy.

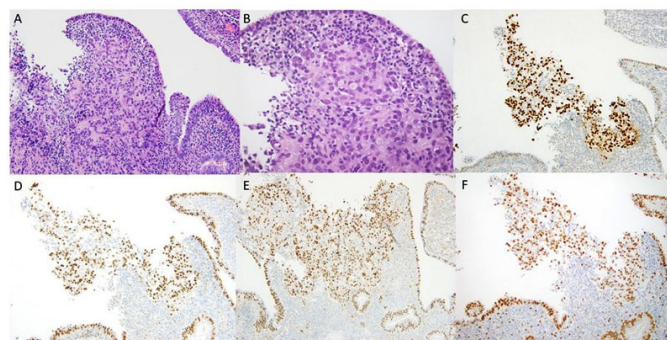


Figure 1: (A) A focus of high grade serous carcinoma underlying benign fallopian tube epithelium (H&E stained section, 20× magnification). (B) A focus of high grade serous carcinoma underlying benign fallopian tube epithelium at higher magnification (H&E stained section, 40× magnification). (C) P53 immunohistochemical stain showing aberrant positive expression in serous carcinoma and wild type expression in surrounding benign fallopian tube epithelium (20× magnification). (D) Pax-8 immunohistochemical stain highlighting carcinoma and benign fallopian tube epithelium (20× magnification). (E) WT-1 immunohistochemical stain highlighting carcinoma and benign fallopian tube epithelium (20× magnification). (F) ER immunohistochemical stain showing positive staining in serous carcinoma and benign fallopian tube epithelium (20× magnification).

Nurfiza Ladak<sup>1</sup>, Alan Marcus<sup>2</sup>, Andrea Hernandez<sup>2</sup>, Esther Adler<sup>3</sup>

**Affiliations:** <sup>1</sup>Resident, Department of Pathology, New York University Langone Health, New York, USA; <sup>2</sup>Assistant Professor of Pathology, New York University Langone Health, New York, USA; <sup>3</sup>Associate Professor of Pathology, Director Pathology Residency Program, New York University Langone Health, New York, USA.

**Corresponding Author:** Nurfiza Ladak, Department of Pathology at New York University Langone Health, 550 1st Avenue, New York 10016, USA; Email: nurfiza.ladak@nyulangone.org

Received: 28 August 2020  
Accepted: 15 October 2020  
Published: 06 November 2020

## DISCUSSION

Incidental gynecologic malignancy is a rare finding in gynecologic specimens resected for benign indications.

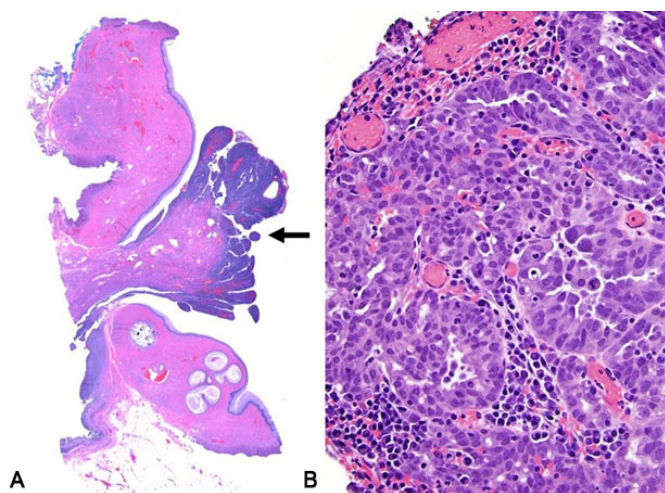


Figure 2: (A) Fallopian tube prolapse with adjacent vaginal epithelium, seen at the periphery. The arrow indicates the focus of high grade serous carcinoma (H&E stained section, 1× magnification). (B) Focus of high grade serous carcinoma (H&E stained section, 40× magnification).

Although no cases involving post-hysterectomy fallopian tube prolapse [1, 2] are present in published literature, there are data from fallopian tube specimens collected for surgical management of other benign conditions. Mahnert et al. reported an incidence of 1.08% of ovarian, peritoneal, and fallopian tube cancers in a study that included 6,360 hysterectomies for benign reasons [3]. Meserve et al. reported an incidence of 0.1% incidental serous tubal intraepithelial carcinoma (STIC) in a study that included 1,747 patients, over the age of 50, who received bilateral salpingectomy and did not have known risk factors (e.g., BRCA1 or BRCA2 mutation) or personal history of cancer [4].

## CONCLUSION

Our case is the first report of a carcinoma arising in the setting of fallopian tube prolapse. It is a reminder that multiple diagnoses, in this case fallopian tube prolapse and high grade serous carcinoma, can exist in a single specimen and that incidental malignancy is a rare but real possibility in all surgical specimens. Furthermore, incidental STIC lesions and serous carcinomas of the fallopian tube have been found to occur predominantly at the fimbriated end of the fallopian tube, as in this case, which emphasizes the importance of submitting the entire fimbriated end for microscopic examination of all fallopian tube specimens, regardless of known risk factors of malignancy.

**Keywords:** Carcinoma, Fallopian, Prolapse, Serous

## How to cite this article

Ladak N, Marcus A, Hernandez A, Adler E. Insidious high grade serous carcinoma of a prolapsing fallopian tube. *J Case Rep Images Pathol* 2020;6:100045Z11NL2020.

Article ID: 100045Z11NL2020

\*\*\*\*\*

doi: 10.5348/100045Z11NL2020CI

## REFERENCES

1. Ouldamer L, Caille A, Body G. Fallopian tube prolapse after hysterectomy: A systematic review. *PLoS One* 2013;8(10):e76543.
2. Sanklecha VM, Sisodia SM, Ansari SAH, Pol S. Posthysterectomy fallopian tube prolapse. *J Midlife Health* 2012;3(1):40–1.
3. Mahnert N, Morgan D, Campbell D, Johnston C, As-Sanie S. Unexpected gynecologic malignancy diagnosed after hysterectomy performed for benign indications. *Obstet Gynecol* 2015;125(2):397–405.
4. Meserve EEK, Mirkovic J, Conner JR, et al. Frequency of “incidental” serous tubal intraepithelial carcinoma (STIC) in women without a history of or genetic risk factor for high-grade serous carcinoma: A six-year study. *Gynecol Oncol* 2017;146(1):69–73.

\*\*\*\*\*

## Author Contributions

Nurfiza Ladak – Conception of the work, Design of the work, Acquisition of data, Analysis of data, Interpretation of data, Drafting the work, Revising the work critically for important intellectual content, Final approval of the version to be published, Agree to be accountable for all aspects of the work in ensuring that questions related to the accuracy or integrity of any part of the work are appropriately investigated and resolved

Alan Marcus – Conception of the work, Design of the work, Acquisition of data, Analysis of data, Interpretation of data, Drafting the work, Revising the work critically for important intellectual content, Final approval of the version to be published, Agree to be accountable for all aspects of the work in ensuring that questions related to the accuracy or integrity of any part of the work are appropriately investigated and resolved

Andrea Hernandez – Conception of the work, Design of the work, Acquisition of data, Analysis of data, Interpretation of data, Drafting the work, Revising the work critically for important intellectual content, Final approval of the version to be published, Agree to be accountable for all

aspects of the work in ensuring that questions related to the accuracy or integrity of any part of the work are appropriately investigated and resolved

Esther Adler – Conception of the work, Design of the work, Acquisition of data, Analysis of data, Interpretation of data, Drafting the work, Revising the work critically for important intellectual content, Final approval of the version to be published, Agree to be accountable for all aspects of the work in ensuring that questions related to the accuracy or integrity of any part of the work are appropriately investigated and resolved

**Guarantor of Submission**

The corresponding author is the guarantor of submission.

**Source of Support**

None.

**Conflict of Interest**

Authors declare no conflict of interest.

**Data Availability**

All relevant data are within the paper and its Supporting Information files.

**Copyright**

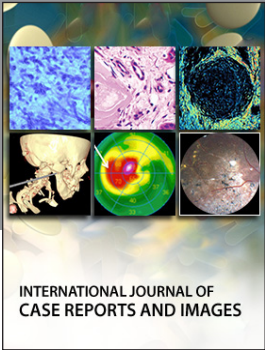
© 2020 Nurfiza Ladak et al. This article is distributed under the terms of Creative Commons Attribution License which permits unrestricted use, distribution and reproduction in any medium provided the original author(s) and original publisher are properly credited. Please see the copyright policy on the journal website for more information.

Access full text article on  
other devices



Access PDF of article on  
other devices





Submit your manuscripts at  
[www.edoriumjournals.com](http://www.edoriumjournals.com)

