EDORIUM Journals

J Case Rep Images Pathol 2023 Jan-Jun;9(1):12–16.
www.ijcripathology.com

CASE REPORT PEER REVIEWED | OPEN ACCESS

Metaplastic breast cancer: A case report and literature review

Lojayne Osman, Dalia Y Ibrahim

ABSTRACT

Introduction: Breast cancer is the second most common cancer among women in the United States. Metaplastic breast cancer is characterized by two or more poorly differentiated cellular types, with epithelial or mesenchymal components. Metaplastic breast carcinoma is a rare and aggressive entity, accounting for less than 1% of invasive breast cancers. Hence, there is insignificant literature and research. Few cases are described in the literature. We report a rare case of metaplastic breast carcinoma with squamous and spindle cell differentiation.

Case Report: An 82-year-old female was diagnosed with metaplastic breast cancer with squamous and spindled differentiation based on histological appearance. She underwent mastectomy, and we track her radiation follow-up.

Conclusion: The report reviews and corroborates existing literature regarding clinical features, histologic characteristics, and treatment methods, and explores genetic components and clinical trials underway.

Keywords: Breast cancer, Metaplastic carcinoma, Triple negative

Lojayne Osman[1], Dalia Y Ibrahim[2], MD

Affiliations: [1]College of Arts and Sciences, The Ohio State University, Columbus, OH 43210, USA; [2]Department of Pathology, University of Toledo Medical Center, 3000 Arlington Avenue, Toledo, OH 43614, USA.

Corresponding Author: Dalia Y Ibrahim, Department of Pathology, University of Toledo Medical Center, Toledo, OH 43614, USA; Email: dalia.ibrahim@utoledo.edu

Received: 02 January 2023
Accepted: 11 March 2023
Published: 05 April 2023

How to cite this article

Osman L, Ibrahim DY. Metaplastic breast cancer: A case report and literature review. J Case Rep Images Pathol 2023;9(1):12–16.

Article ID: 100069Z11LO2023

****

doi: 10.5348/100069Z11LO2023CR

INTRODUCTION

Metaplastic breast carcinoma (MBC), as a variant of triple-negative breast cancer (TNBC), is responsible for less than 1% of all invasive breast cancers [1]. The World Health Organization (WHO) classifies metaplastic carcinomas into five types, including the aggressive squamous and spindle cell types [2]. Because of its rarity, metaplastic squamous and spindle cell carcinomas are difficult to diagnose. Spindle alone can be deceiving in its presentation due to its resemblance to sarcoma, and accounts for a mere 0.08%, while squamous accounts for up to 0.1% of breast carcinomas [1, 2]. These cancers are also generally very aggressive and yield poor prognosis due to their resistance to orthodox systemic therapy, varied cell behavior, and large size: a report shows that the average diameter of such tumors is 4 cm [3].

There are few reports and data regarding metaplastic carcinomas of the breast. Causes, determinants of, and histological appearances are yet to be agreed on in the scientific community [4]. We present a rare case of metaplastic carcinoma with squamous and spindled cell differentiation.

CASE REPORT

The patient is an 82-year-old female with a history of right nasal basal cell carcinoma, recurrent sinusitis, and chronic anxiety. Her family history is significant

for a sister with a basal cell carcinoma. There is no prior history of squamous cell carcinoma or extensive sunlight exposure. The patient presented to the surgical clinic for an evaluation of breast lesions. Two years prior, the patient noticed a palpable mass in her left breast. The mass had since increased in size. An ultrasound revealed a complex cystic and solid lesion, suspicious findings for papillary neoplasm (Figure 1). A biopsy and subsequent mastectomy were performed.

Gross examination of the mastectomy specimen demonstrated a weight of 1335 grams and it measured 27 × 16.5 × 6.7 cm. Serial sectioning of the breast revealed a complex mass measuring 7 × 6 × 5 cm (Figure 2), extending laterally from the nipple to the mid axillary line, and was associated with nipple inversion and skin changes. Cut surface of the mass was mostly firm yellow-tan with areas of yellow cheesy (possibly necrotic) material. There are areas of brownish coloration as well as cystic areas with papillary infolding/nodular areas. The mass appeared to be grossly separate from the overlying nipple/skin. Sentinel lymph node biopsy and frozen section analysis was negative for lymph node metastasis. Microscopic images reveal keratinized squamous cell (Figures 3 and 4) and spindle cell (Figure 4) differentiation. Immunostaining was negative for progesterone and estrogen receptors, as well as HER2.

After mastectomy, the patient underwent a positron emission tomography (PET) scan with two suspicious small, mildly avid lesions in the right lung, for which close interval follow-up computed tomography (CT) imaging in three months was recommended. She is also completing radiation to the left chest wall and regional lymph nodes, and experiences side effects.

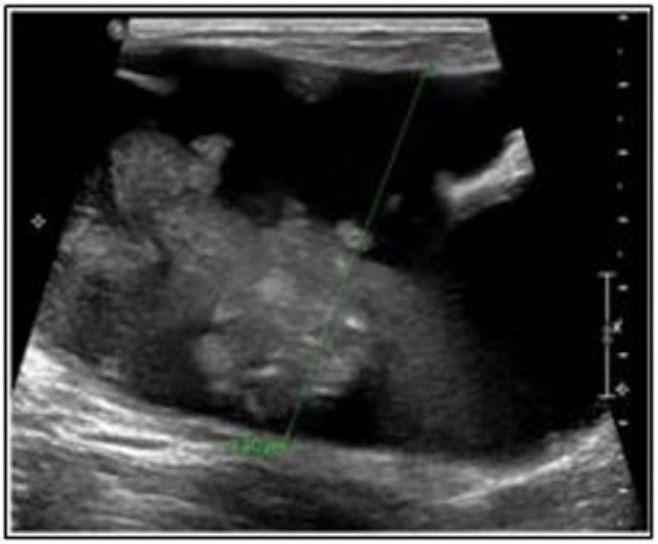

Figure 1: Ultrasound on the left breast revealing a complex solid and cystic lesion measuring 5.9 cm.

Figure 2: Gross image of the serially sectioned mastectomy specimen demonstrates complex mass measuring 7 × 6 × 5 cm.

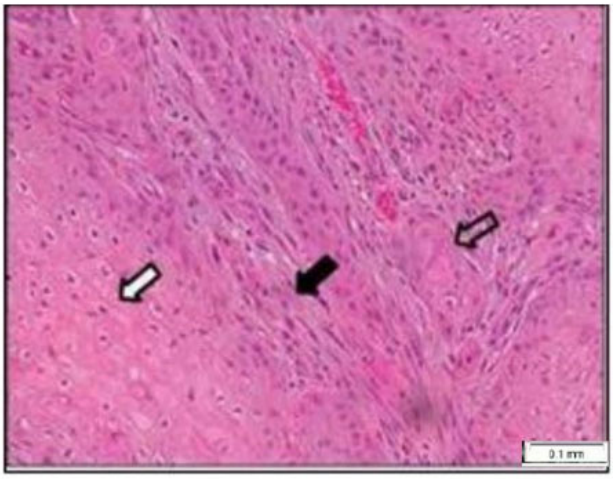

Figure 3: Microscopic image showing both spindle cell (black arrow) and squamous cell (white arrow) differentiation with keratin pearls (open arrow).

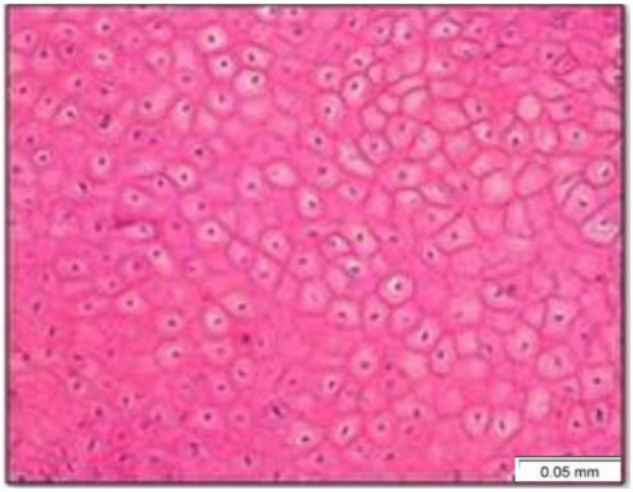

Figure 4: Microscopic image showing atypical keratinized squamous cells.

DISCUSSION

Background

Metaplastic carcinoma of the breast is considered one of the rarest occurrences, accounting for less than 1% of all invasive breast cancers [1]. While there are different subtypes depending on the types of cells visible, all types are currently treated the same way. This is because, having only been recognized as a disease entity in 2000, there is little information about treatment and outcomes [5]. The current 5-year disease-free survival rate of MBC is as low as 40%, though studies have reported spindle cell survival rates as low as 28% [6, 7]. Ninety percent of the time, metaplastic breast cancer is triple-negative and is characterized by gene instability, making systemic treatment difficult and ineffective [4]. The working theory about the manifestation of MBC is that it begins as an invasive ductal carcinoma and undergoes a series of genetic mutations to transform into epithelial cells. The process is termed mesenchymal transformation [5].

Clinical features

The case presented corroborates existing literature on MBC. The National Cancer Database conducted a study from 2001–2003 and found that, compared to invasive ductal carcinoma (IDC), patients diagnosed with MBC were generally older (median age of 61.1 versus 59.7 for IDC) and predominantly of African American and Hispanic origin (15.1% and 5.5%, respectively). The tumor sizes were also significantly larger: the group with MBC had only 29.5% of T1 tumors (classified on size and extent of the tumor), while the IDC group had 65.2% [8]. Because of this larger tumor size, breast-conserving surgery is not a viable option for most patients with MBC. In addition, although lymphatic spread is rare, it has been found in up to 40% of cases [9]. Axillary lymph node dissection (ALND) has therefore been replaced with sentinel lymph node biopsy (SLNB) [10]. A study has found that chances of recurrence with MBC (34%) are significantly higher than TNBC (15.5%) [11]. The same study has concluded that the likelihood of death show a similar trend, with 39% of MBC patients dying compared to 16% of TNBC patients [11].

Histologic characteristics

Histologically, lack of consensus results in a variety of appearances and diagnoses. Metaplastic breast carcinoma is poorly differentiated heterogeneous cancer with ductal cells amidst spindle and/or squamous epithelial cells [1]. The Wargotz-Norris classification divides metaplastic breast cancer into two further categories, carcinosarcoma and matrix-producing type, in addition to spindle cell and squamous cell [12–15]. Each type's histological characteristics are shown in Table 1.

Table 1: Histologic features of Wargotz-Norris of metaplastic breast cancer based on subtypes

Wargotz-Norris classification	Histologic features
Squamous cell carcinoma (epithelial)	Infiltrating squamous cells with polygonal cells and possible keratin pearl formation [15].
Spindle cell carcinoma (epithelial)	Poorly cohesive sheets of atypical spindle cells, often presenting granulation tissue or as low-grade sarcoma [14].
Matrix-producing	Pure carcinoma transformed to cartilaginous matrix or osseous stromal matrix with no spindle component [13].
Carcinosarcoma	Malignant epithelium and neoplastic stromal cells [12].

Genetics

Metaplastic carcinomas have been shown to be genetically heterogeneous, thus explaining the variety of subtypes that occur. However, the subtypes are subject to their own genetic makeup; chondroid matrix-producing carcinoma lacks PIK3CA aberrations, which are common among other subtypes [16]. The clinical implications of the findings of genetic mutations suggest an efficacy of PI-3 inhibitors, although further research is necessary [17]. Matrix-producing carcinoma and carcinoma with mesenchymal differentiation also lack telomerase reverse transcriptase (TERT) promoter mutations. On the other hand, TERT promoter mutations were found in 39% of spindle and/or squamous differentiation (47% in another study), and is found to result in poor response to chemotherapy and lower prognosis [2, 16]. Another study has found that metaplastic breast cancer is at least partially composed of clonal cells with these distinct genetic aberrations, further supporting the evolution model, and suggesting the genetic aberrations are responsible for different phenotypes and disease progression [18]. The genetic defects present in MBC are hotspots for further investigation.

Treatment

Chemotherapy is often the path taken when dealing with MBC given the hormonal resistance of the disease; however, there is no specific chemotherapy treatment developed or recommended for MBC, and effectiveness is still uncertain. Reports suggest that MBC is chemoresistant; Mayo Clinic cites that, of the 33% of MBC patients that received chemotherapy, only one patient experienced a partial response [11]. Invasive ductal carcinoma treatments are still being used for MBC treatment [8]. Radiation is also used to treat MBC. While a study shows that postmastectomy radiation results in a 33% decreased rate of death of any cause and post-

lumpectomy radiation yields a 36% decrease of death of any cause, patients still experience an increased risk of tumor recurrence [19]. Adjuvant chemotherapy has been shown to be effective, with low recurrence (64%) and higher survival rates (69%) [20].

Clinical trials

A genetic study has found that a total of 23 genetic alterations were found in 83.3% of subjects, 50% of them harboring PI3K aberrations [21]. Another study revealed similar findings; 61% of MBC patients studied had PI3K pathways mutations, based on histologic subtype. No chondroid matrix-producing MBC had PI3K aberrations, while 94% of the other subtypes showed pathway aberrations [16]. As a result of these findings, there are clinical trials underway targeting the PI3K-AKT-mTOR pathway, the signal pathway associated with metabolism, proliferation, and cell survival. Aberration of the pathway through critical genes yields potential cancer treatment methods. A study shows that PI3K aberration in MBC patients resulted in significant improvement in objective response rate of 31% versus 0%, and a clinical benefit rate of 40% [22]. Similarly, taxane chemotherapy used in one study on 17 patients resulted in 17.6% of these patients to exhibit a partial response, as opposed to 0% of patients who responded to vinorelbine or cyclophosphamide-based therapy [23]. Further research and experimentation is still necessary to confirm the results and hypotheses of both studies. There are still no specific treatments cited for metaplastic breast carcinoma; invasive ductal carcinoma treatments are being used and yield subpar results. Of note, one case series highlighted the potential utility of immune checkpoint inhibitors in advanced cases of MBC [24].

CONCLUSION

Metaplastic breast carcinoma is a rare aggressive malignancy associated with poor prognosis. This report reviews and supports existing literature regarding clinical features, histologic characteristics, and treatment modalities. Herein, we also explore the genetic alterations associated with this malignancy such as somatic mutations in TP53, PI3K MAPK, RB1, and Wnt pathways genes. Because MBC is rare, only a few trials have been aimed to specifically study this entity. Nevertheless, several clinical trials investigating novel treatment strategies for triple negative breast cancers also permit for MBC enrolment. Immune checkpoint inhibitors might prove useful in advanced cases of this disease. Further clinical trials are warranted to explore more therapeutic options for this rare aggressive tumor.

REFERENCES

1. Schwartz TL, Mogal H, Papageorgiou C, Veerapong J, Hsueh EC. Metaplastic breast cancer: Histologic characteristics, prognostic factors and systemic treatment strategies. Exp Hematol Oncol 2013;2(1):31.
2. McMullen ER, Zoumberos NA, Kleer CG. Metaplastic breast carcinoma: Update on histopathology and molecular alterations. Arch Pathol Lab Med 2019;143(12):1492–6.
3. Carter MR, Hornick JL, Lester S, Fletcher CDM. Spindle cell (sarcomatoid) carcinoma of the breast: A clinicopathologic and immunohistochemical analysis of 29 cases. Am J Surg Pathol 2006;30(3):300–9.
4. Alaoui M'hamdi H, Abbad F, Rais H, et al. Rare variant of metaplastic carcinoma of the breast: A case report and review of the literature. J Med Case Rep 2018;12(1):43.
5. https://www.mpbcalliance.org/metaplastic-breast-cancer-pathology/
6. Song Y, Liu X, Zhang G, et al. Unique clinicopathological features of metaplastic breast carcinoma compared with invasive ductal carcinoma and poor prognostic indicators. World J Surg Oncol 2013;11:129.
7. Okushiba S, Minagawa H, Shimizu M, et al. A case of spindle cell carcinoma of the breast—Long survival achieved by multiple surgical treatment. Breast Cancer 2001;8(3):238–42.
8. Pezzi CM, Patel-Parekh L, Cole K, Franko J, Klimberg VS, Bland K. Characteristics and treatment of metaplastic breast cancer: Analysis of 892 cases from the National Cancer Data Base. Ann Surg Oncol 2007;14(1):166–73.
9. McKinnon E, Xiao P. Metaplastic carcinoma of the breast. Arch Pathol Lab Med 2015;139(6):819–22.
10. Giuliano AE, Jones RC, Brennan M, Statman R. Sentinel lymphadenectomy in breast cancer. J Clin Oncol 1997;15(6):2345–50.
11. El Zein D, Hughes M, Kumar S, et al. Metaplastic carcinoma of the breast is more aggressive than triple-negative breast cancer: A study from a single institution and review of literature. Clin Breast Cancer 2017;17(5):382–91.
12. Rayson D, Adjei AA, Suman VJ, Wold LE, Ingle JN. Metaplastic breast cancer: Prognosis and response to systemic therapy. Ann Oncol 1999;10(4):413–9.
13. Wargotz ES, Norris HJ. Metaplastic carcinomas of the breast. III. Carcinosarcoma. Cancer 1989;64(7):1490–9.
14. Wargotz ES, Norris HJ. Metaplastic carcinomas of the breast. I. Matrix-producing carcinoma. Hum Pathol 1989;20(7):628–35.
15. Wargotz ES, Deos PH, Norris HJ. Metaplastic carcinomas of the breast. II. Spindle cell carcinoma. Hum Pathol 1989;20(8):732–40.
16. Wargotz ES, Norris HJ. Metaplastic carcinomas of the breast. IV. Squamous cell carcinoma of ductal origin. Cancer 1990;65(2):272–6.
17. Krings G, Chen YY. Genomic profiling of metaplastic breast carcinomas reveals genetic heterogeneity and relationship to ductal carcinoma. Mod Pathol 2018;31(11):1661–74.

18. Moulder S, Helgason T, Janku F, et al. Inhibition of the phosphoinositide 3-kinase pathway for the treatment of patients with metastatic metaplastic breast cancer. Ann Oncol 2015;26(7):1346–52.
19. Geyer FC, Weigelt B, Natrajan R, et al. Molecular analysis reveals a genetic basis for the phenotypic diversity of metaplastic breast carcinomas. J Pathol 2010;220(5):562–73.
20. Tseng WH, Martinez SR. Metaplastic breast cancer: To radiate or not to radiate? Ann Surg Oncol 2011;18(1):94–103.
21. Cimino-Mathews A, Verma S, Figueroa-Magalhaes MC, et al. A clinicopathologic analysis of 45 patients with metaplastic breast carcinoma. Am J Clin Pathol 2016;145(3):365–72.
22. Zhai J, Giannini G, Ewalt MD, et al. Molecular characterization of metaplastic breast carcinoma via next-generation sequencing. Hum Pathol 2019;86:85–92.
23. Basho RK, Gilcrease M, Murthy RK, et al. Targeting the PI3K/AKT/mTOR pathway for the treatment of mesenchymal triple-negative breast cancer: Evidence from a phase 1 trial of mTOR inhibition in combination with Liposomal Doxorubicin and Bevacizumab. JAMA Oncol 2017;3(4):509–15.
24. Kim I, Rajamanickam V, Bernard B, et al. A case series of metastatic metaplastic breast carcinoma treated with anti-PD-1 therapy. Front Oncol 2021;11:635237.

****

Author Contributions

Lojayne Osman – Design of the work, Analysis of data, Interpretation of data, Drafting the work, Final approval of the version to be published, Agree to be accountable for all aspects of the work in ensuring that questions related to the accuracy or integrity of any part of the work are appropriately investigated and resolved

Dalia Y Ibrahim – Conception of the work, Design of the work, Acquisition of data, Analysis of data, Interpretation of data, Revising the work critically for important intellectual content, Final approval of the version to be published, Agree to be accountable for all aspects of the work in ensuring that questions related to the accuracy or integrity of any part of the work are appropriately investigated and resolved

Guarantor of Submission

The corresponding author is the guarantor of submission.

Source of Support

None.

Consent Statement

Written informed consent was obtained from the patient for publication of this article.

Conflict of Interest

Authors declare no conflict of interest.

Data Availability

All relevant data are within the paper and its Supporting Information files.

Copyright

© 2023 Lojayne Osman et al. This article is distributed under the terms of Creative Commons Attribution License which permits unrestricted use, distribution and reproduction in any medium provided the original author(s) and original publisher are properly credited. Please see the copyright policy on the journal website for more information.

Access full text article on other devices

Access PDF of article on other devices



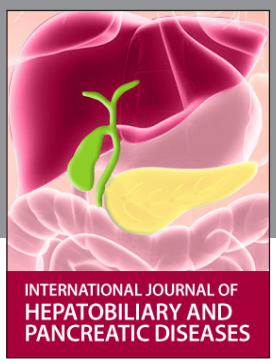

Submit your manuscripts at
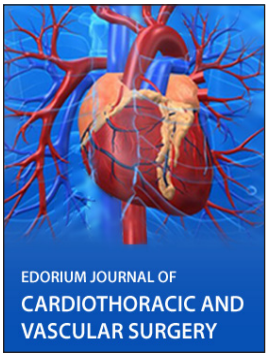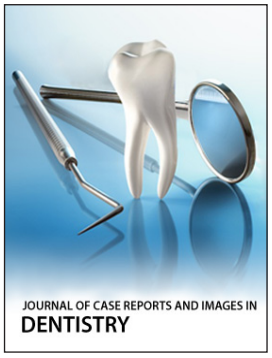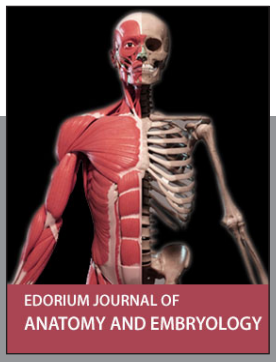
www.edoriumjournals.com