

## CASE REPORT

## PEER REVIEWED | OPEN ACCESS

# Pneumatosis cystoides intestinalis revealed by an occlusive syndrome: A case report

Franck Auguste Hermann Adémayali Ido, Aimé Sosthène Ouedraogo, Ibrahim Savadogo, Rakiswendé Alexis Ouedraogo, Souleymane Ouattara

## ABSTRACT

**Introduction:** Pneumatosis cystoides intestinalis is a rare condition characterized by the presence of gas cysts in the intestinal wall. It can affect different segments of the digestive tract. Male patients over 50 years old seem to be more affected. Classically, one opposes the primary or idiopathic forms and the secondary forms.

**Case Report:** We report the case of a 62-year-old female patient with a history of treated peptic ulcers, who presented with episodes of intermittent atypical abdominal pain that worsened abruptly. The physical examination revealed a surgical abdomen with tenderness to palpation. The patient underwent a jejunal resection. The pathological examination showed macroscopically an intestinal fragment with confluent subserosal and intestinal intraparietal bullae. On opening, the portion containing the bullae was thickened, infarcted, congestive, hemorrhagic, and brittle with narrowing

of the intestinal lumen. The bullae are tense and leave serosities. On histological examination, the intestinal wall was very congestive with hemorrhagic patches of suffusion. There were optically empty cystic formations that does not communicate with the digestive lumen. The adjacent mucosa is the site of a moderate subacute inflammatory reaction.

**Conclusion:** Pneumatosis cystoides intestinalis is a rare and usually benign pathology. The symptoms, when they exist, are not specific. Its physiopathology is still very much debated. The prognosis is generally good. The knowledge of this pathology is necessary to avoid invasive explorations and heavy treatment without interest for the patient.

**Keywords:** Cysts, Gas, Intestinal, Pathology

### How to cite this article

Ido FAHA, Ouedraogo AS, Savadogo I, Ouedraogo RA, Ouattara S. Pneumatosis cystoides intestinalis revealed by an occlusive syndrome: A case report. J Case Rep Images Pathol 2023;9(1):29–33.

Article ID: 100072Z11FI2023

\*\*\*\*\*

doi: 10.5348/100072Z11FI2023CR

Franck Auguste Hermann Adémayali Ido<sup>1</sup>, Aimé Sosthène Ouedraogo<sup>2</sup>, Ibrahim Savadogo<sup>3</sup>, Rakiswendé Alexis Ouedraogo<sup>4</sup>, Souleymane Ouattara<sup>5</sup>

**Affiliations:** <sup>1</sup>Assistant Professor, Joseph KI-ZERBO University, Department of Anatomy and Pathological Cytology, CHU - Tengandogo, Ouagadougou, Burkina Faso; <sup>2</sup>Associate Professor, Joseph KI-ZERBO University, Department of Anatomy and Pathological Cytology, CHU - Bogodogo, Ouagadougou, Burkina Faso; <sup>3</sup>Assistant Professor, Department of Anatomy and Pathological Cytology, Ouahigouya University, CHUR - Ouahigouya, Burkina Faso; <sup>4</sup>Assistant Professor at Joseph KI-ZERBO University, Department of Histo-embryo-cytogenetics, CHU - Bogodogo, Ouagadougou, Burkina Faso; <sup>5</sup>Hospital Assistant, University Hospital Center CHU - Tengandogo, Ouagadougou, Burkina Faso.

**Corresponding Author:** Franck Auguste Hermann Adémayali Ido, 11 BP 104 CMS, Ouagadougou 01, Ouagadougou, Burkina Faso; Email: idofranck@yahoo.fr

Received: 21 April 2023

Accepted: 11 May 2023

Published: 26 May 2023

## INTRODUCTION

Pneumatosis cystoides intestinalis is defined by the presence of gas cysts in the wall of the digestive tract. It is a rare condition that is probably under-diagnosed because of its paucisymptomatic nature. It was first described in 1730 by DUVERNOY during an autopsy [1–3]. The sites of predilection are the small intestine and the colon. Its pathogenesis is still debated and several hypotheses have been proposed [1, 2]. It is classic to oppose the primary or idiopathic forms (15%), located mainly in the left colon

and whose evolution is generally benign, to the secondary forms (85%) located essentially in the small intestine, whose pathological associations are numerous and whose evolution is that of the underlying pathology [1–3]. We report here a case of Pneumatosis cystoides intestinalis revealed by an occlusive syndrome. With this case and through a review of the literature we will discuss the anatomical and clinical particularities of this little-known pathology.

## CASE REPORT

This was a 62-year-old female patient with a history of treated peptic ulcers, who presented with episodes of intermittent atypical abdominal pain that worsened abruptly accompanied by vomiting. The physical examination revealed a surgical abdomen with tenderness to palpation. The radiological examination of the abdomen without preparation and the abdominal ultrasound concluded to an occlusive syndrome by intestinal invagination. The patient underwent a jejunal resection 50 cm from the duodeno-jejunal junction. Intraoperatively, a moderate pyloric stenosis was discovered.

The pathological examination showed macroscopically an intestinal fragment of 34×2 to 4 cm. Confluent subserosal and intestinal intraparietal bullae were observed on 12 cm, at 8 cm from the distal section and at 12 cm from the proximal section. The size of the bullae varied from 0.5 to 1.5 cm (Figure 1A). On opening, the portion containing the bullae was thickened, infarcted, congestive, hemorrhagic, and brittle with narrowing of the intestinal lumen. The bullae are tense and leave serositis (Figure 1B).

On histological examination, the intestinal wall was very congestive with hemorrhagic patches of suffusion. There were optically empty cystic formations of variable size delimited by a thin wall that does not communicate with the digestive lumen (Figure 2A). Serohemorrhagic serosities were observed in the lumen of some cysts (Figure 2B). The adjacent mucosa is the site of a moderate subacute inflammatory reaction

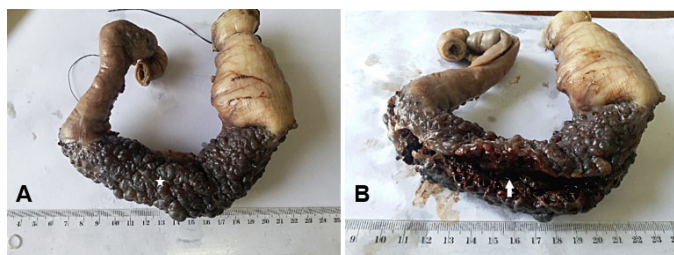


Figure 1: (A) Macroscopy showing confluent subserosal and intraparietal bubbles ranging in size from 0.5 to 1.5 cm (white star). (B) Macroscopy showing a thickened, congestive, and hemorrhagic intestinal wall at the opening. The bullae are tense and give rise to serosities (white arrow).

with leukocytes and macrophages. The cystic walls are fibrous made of fibroblasts and contain histiocytes (Figure 3A and B).

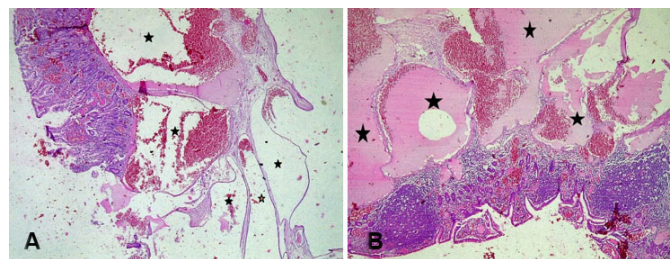


Figure 2: (A) Microscopy G100, HE stain, showing an intestinal wall with optically empty bubbles at the site of hemorrhagic suffusion (black stars). The bubbles do not communicate with the intestinal lumen. (B) Microscopy G100, HE stain, showing an intestinal wall with serosity filled bullae (black stars). The mucosa is congestive with a subacute inflammatory reaction.

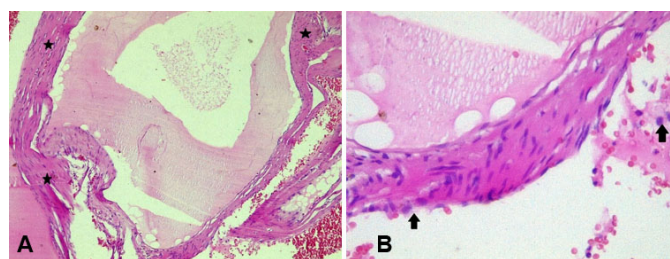


Figure 3: (A) Microscopy G100, HE stain, showing a fibrous cystic wall (black stars) made of fibroblasts. (B) Microscopy G100, HE stain, showing a fibrous cystic wall made of fibroblasts with foamy histiocytes in the wall and in the cystic lumen (black arrows).

## DISCUSSION

Pneumatosis cystoides intestinalis is a relatively rare condition. Its frequency is probably underestimated, especially in countries with limited resources. Although a female predominance has been reported in some series, cystic pneumatosis is more frequent in males over 50 years of age with a sex ratio of 1 to 3.5 [1–4].

Pneumatosis cystoides intestinalis is primary, i.e., without any presumed causal pathology in 15% of cases. It is secondary, associated with a favorable or causal condition in 85% of cases. Primitive forms are located preferentially in the left colon, whereas secondary forms more frequently affect the right colon and small intestine [1, 2].

Numerous digestive and extra-digestive pathologies, from the most trivial to the most serious, have been associated with Pneumatosis cystoides intestinalis. When there is a suspicion of Pneumatosis cystoides intestinalis on imaging, a thorough clinical and paraclinical investigation should be carried out to assess the severity of the damage. This allows the early detection of acute ischemic lesions which are true medical and surgical emergencies [1, 2, 5–8].

The digestive pathologies involved in the occurrence of *Pneumatosis cystoides intestinalis* are numerous. These include pyloric stenosis, often secondary to antropyloric ulcers. It is thought to be responsible for one-third (1/3) of all cases of *Pneumatosis cystoides intestinalis* and about 50% of the forms localized in the small intestine. In our patient's case, pyloric stenosis can be cited as one of the etiological factors, as pyloric stenosis was discovered intraoperatively in our patient, who had a history of peptic ulcer disease. Celiac disease, chronic pseudo-occlusions, inflammatory bowel disease, ischemic enteropathy, and trauma after digestive endoscopies are other digestive conditions associated with *Pneumatosis cystoides intestinalis* [1, 2].

The extra-digestive conditions associated with *Pneumatosis cystoides intestinalis* are diverse and varied. The incriminated pulmonary affections can be congenital like cystic fibrosis or acquired like asthma or other chronic obstructive pulmonary diseases. Our patient is asthmatic, which is another etiological factor of her *Pneumatosis cystoides intestinalis* [1, 2].

Infectious pathologies associated with *Pneumatosis cystoides intestinalis* include those associated with acquired immunodeficiency syndrome (AIDS). These include cryptosporidiosis, cytomegalovirus, and mycobacteriosis [1, 2].

Systemic diseases are also often associated with *Pneumatosis cystoides intestinalis*. These include scleroderma, dermatomyositis, and systemic lupus erythematosus [1, 2].

*Pneumatosis cystoides intestinalis* is also associated with iatrogenic causes, including prolonged exposure to trichloroethylene, which is thought to act as an anesthetic on the autonomic nervous system, resulting in a disturbance of intestinal peristalsis and promoting the development of emphysema. Trichloroethylene and its metabolites would also have an action on the intestinal bacterial flora favoring the proliferation of gas-producing bacteria. Inhibitors of  $\alpha$ -glucosidase have the effect of reducing the absorption of carbohydrates by slowing their digestion. This results in a large amount of unabsorbed carbohydrate whose fermentation will produce large amounts of hydrogen, oxygen dioxide, and methane. These gases will be responsible for an increase in intraluminal pressure, which is the cause of pneumatosis [1, 2].

Finally, *Pneumatosis cystoides intestinalis* can occur after organ transplantation. In this context, it is most often benign, but rare serious cases can occur, particularly after bone marrow transplantation [1, 2].

These different pathological associations are the basis of several theories proposed to explain the pathophysiology of *Pneumatosis cystoides intestinalis*. These different theories can be grouped into three main theories.

A first theory, called "mechanical," is based on the principle that intraluminal hyperpressure secondary to digestive obstruction will cause submucosal dissection from the digestive lumen. The mechanical theory largely

explains the association of digestive disorders with cystic fibrosis of the intestine [1–8].

A second theory, called "pulmonary," defends the hypothesis according to which a thoracic hyperpressure present in subjects suffering from chronic obstructive pulmonary disease or asthma would be responsible for a diffusion of gas toward the digestive serosa. This theory has limitations in that it does not explain the left colonic predominance of the cysts, nor their richness in hydrogen, which is much higher than that of the alveolar air [1–8].

A third theory called "bacterial" incriminates a pullulation of anaerobic germs responsible for a hyperproduction of gases which penetrate the digestive wall by means of efractions or hyperpermeability of the mucosa. This theory is based on the results of the analysis of gas bubbles of pneumatosis which have a high content of hydrogen and nitrogen in relation to a bacterial fermentation which would be linked to an anaerobic microbial pullulation [1–8].

This third theory is the most commonly accepted and is supported by a number of arguments. Firstly, the hydrogen content measured during a respiratory test in patients with digestive pneumatosis is higher than normal, suggesting an increase in anaerobic activity due to a lack of bacterial flora transforming hydrogen into methane. Secondly, experimental injection of anaerobic germs into the submucosa of animals is responsible for digestive pneumatosis. Finally, several publications report the disappearance of intestinal pneumatosis after treatment with hyperbaric oxygen and also with metronidazole [1, 2].

Clinically, *Pneumatosis cystoides intestinalis* is often paucisymptomatic. In the symptomatic forms, symptoms are related to luminal occlusion, extrinsic compression, or mucosal distress facilitated by the cysts [1–11].

It is usual to distinguish between small bowel and colonic involvement. *Pneumatosis cystoides intestinalis* of the small intestine manifests itself by high digestive symptoms such as vomiting and abdominal pain. Colonic *Pneumatosis cystoides intestinalis* is more likely to be revealed by lower digestive symptoms such as diarrhea, rectal bleeding, mucus in the stool or intestinal obstruction [1, 2].

Radiological examinations are essential for the diagnosis of *Pneumatosis cystoides intestinalis* because of the lack of specificity of clinical signs. It allows to establish the diagnosis and to assess the prognosis. Abdominal computed tomography (CT) scan is the best examination for the diagnosis of *Pneumatosis cystoides intestinalis*. Computed tomography images show intramucosal aerial images and sometimes allow to specify the primary or secondary character [1, 2, 7].

Colonoscopy is most useful for colonic locations of *Pneumatosis cystoides intestinalis*. The characteristic appearance is the presence of multiple translucent polypoid formations with a thin wall covered by normal mucosa [9]. The bursting of the polypoid formations causes a peculiar sound called "popping sound" [1–3, 6, 7].



Anatomopathological study is mainly performed for severe cases requiring surgery. In about 40% of cases, the small intestine is involved, with cysts that are most often sub-serous, and in about 35% of cases, the colon, with cysts located in the submucosa and exceptionally in the muscularis. Simultaneous involvement of the colon and small bowel is found in about 20% of cases [6, 9]. Cysts range in size from a few millimeters to a few centimeters.

Histologically, the cysts have a thin wall that does not communicate with the lumen of the digestive tract. Flattened histiocytes are found in the cystic wall in young forms and a few giant cells in aged forms. In some cases, the adjacent mucosa is the site of a moderate inflammatory reaction with leukocytes and macrophages [1, 2].

Pneumatosis cystoides intestinalis is a generally paucisymptomatic pathology. Treatment is usually medical and is effective in more than half of the cases. The proposed treatments are closely related to the physiopathological theories. Antibiotic therapy is proposed in order to reduce the bacterial production of hydrogen. Antibiotics that have shown some effectiveness are metronidazole, ampicillin, or fluoroquinolones. Hyperbaric oxygen therapy is used for its anti-anaerobic power and for its ability to collapse cysts by promoting exchanges with the blood [8]. Other therapies such as nasogastric decompression, octreotide administration, or endoscopic fenestration have shown mixed results. Surgical treatment is indicated mainly for complicated cases and consists of segmental resection of the affected intestinal portion [1, 2, 7–11].

## CONCLUSION

Pneumatosis cystoides intestinalis is a rare and usually benign pathology. The symptoms, when they exist, are not specific. Its physiopathology is still very much debated. Its diagnosis is based on radiological examinations, especially CT scan. Pathological examination is performed only in severe forms that require surgical treatment. The prognosis is generally good. The knowledge of this pathology is necessary to avoid invasive explorations and heavy treatment without interest for the patient.

## REFERENCES

1. Laclotte-Duhoux C, Bigard MA. Pneumatose kystique intestinale. *EMC - Gastro-Entérologie* 2010;27(3):1.
2. Bigard MA, Laclotte-Duhoux C. Pneumatose kystique intestinale. *EMC - Gastro-Entérologie* 2019;14(1):1–9.
3. El Hattabi K, Lafkih O, Bensardi F, Elbakouri A, Bouali M, Fadil A. Pneumatosis cystoides intestinalis with pneumoperitoneum secondary to stenosing pyloro-duodenal peptic ulcer: Case series of three patients and literature review. *Int J Surg Case Rep* 2021;81:105772.
4. El Matiallah MA, El Bouhaddouti H, Mouaqit O, El Benjelloun B, Ousadden A, Taleb KA. Intestinal cystic pneumatosis revealed by stenosis of a gastrointestinal

anastomosis: Report of a case. [Article in French]. *Pan Afr Med J* 2013;15:125.

5. Etoke EC, Miguil MS, Iben Loualid Y, et al. La Pneumatose kystique intestinale secondaire a un ulcere peptique: A propos d'un cas Chu-Mohamed VI Marrakech, Maroc, Université Cadi Ayyad Service Chirurgie Viscerale. *Int J Adv Res* 2022;10(11):874–8.
6. Chan Sui Ko A, Brault C, Medioni L, Hakim S, Duhaut P, Schmidt J. Une découverte fortuite de pneumopéritoine: La pneumatose kystique intestinale. *La Revue de Médecine Interne* 2018;39(Suppl 2):A149.
7. Di Pietropaolo M, Trinci M, Giangregorio C, Galluzzo M, Miele V. Pneumatosis cystoides intestinalis: Case report and review of literature. *Clin J Gastroenterol.* 2020;13(1):31–6.
8. Mitsuyoshi Y, Takakura K, Kobayashi T, et al. Chronic intestinal pseudo-obstruction with pneumatosis cystoides intestinalis in a patient with systemic sclerosis: A case report. *Medicine (Baltimore)* 2019;98(18):e15480.
9. Kacem HH, Kharrasse G, El Harroudi T. Rare cause of intestinal obstruction: Intestinal cystic pneumatosis. [Article in French]. *Pan Afr Med J* 2014;19:230.
10. Nagata S, Ueda N, Yoshida Y, Matsuda H. Pneumatosis coli complicated with intussusception in an adult: Report of a case. *Surg Today* 2010;40(5):460–4.
11. El Bouhaddouti H, Abdelmalek, El Bachir B, Ibn Majdoub K, Khalid M, Aït Taleb K. Cystic pneumatosis ileal revealed by a small bowel volvulus. [Article in French]. *Pan Afr Med J* 2010;6:9.

\*\*\*\*\*

## Author Contributions

Franck Auguste Hermann Adémayali Ido – Conception of the work, Interpretation of data, Drafting the work, Final approval of the version to be published, Agree to be accountable for all aspects of the work in ensuring that questions related to the accuracy or integrity of any part of the work are appropriately investigated and resolved

Aimé Sosthène Ouedraogo – Conception of the work, Interpretation of data, Drafting the work, Final approval of the version to be published, Agree to be accountable for all aspects of the work in ensuring that questions related to the accuracy or integrity of any part of the work are appropriately investigated and resolved

Ibrahim Savadogo – Conception of the work, Interpretation of data, Drafting the work, Final approval of the version to be published, Agree to be accountable for all aspects of the work in ensuring that questions related to the accuracy or integrity of any part of the work are appropriately investigated and resolved

Rakiswendé Alexis Ouedraogo – Conception of the work, Interpretation of data, Drafting the work, Final approval of the version to be published, Agree to be accountable for all aspects of the work in ensuring that questions related to the accuracy or integrity of any part of the work are appropriately investigated and resolved

Souleymane Ouattara – Conception of the work, Interpretation of data, Drafting the work, Final approval of the version to be published, Agree to be accountable for all aspects of the work in ensuring that questions related to the accuracy or integrity of any part of the work are appropriately investigated and resolved

**Guarantor of Submission**

The corresponding author is the guarantor of submission.

**Source of Support**

None.

**Consent Statement**

Written informed consent was obtained from the patient for publication of this article.

**Conflict of Interest**

Authors declare no conflict of interest.

**Data Availability**

All relevant data are within the paper and its Supporting Information files.

**Copyright**

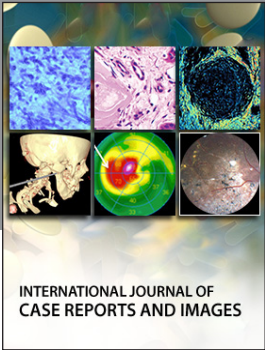
© 2023 Franck Auguste Hermann Adémayali Ido et al. This article is distributed under the terms of Creative Commons Attribution License which permits unrestricted use, distribution and reproduction in any medium provided the original author(s) and original publisher are properly credited. Please see the copyright policy on the journal website for more information.

Access full text article on  
other devices



Access PDF of article on  
other devices





Submit your manuscripts at  
[www.edoriumjournals.com](http://www.edoriumjournals.com)

